

“healing one WISH at a time.”



# PI-020 In-situ autologous whole blood clot formation in dermal ulceration using a novel wound bed stimulation method for enhanced vascularization and the perpetuation of the proliferative phase in wound healing.

## Introduction

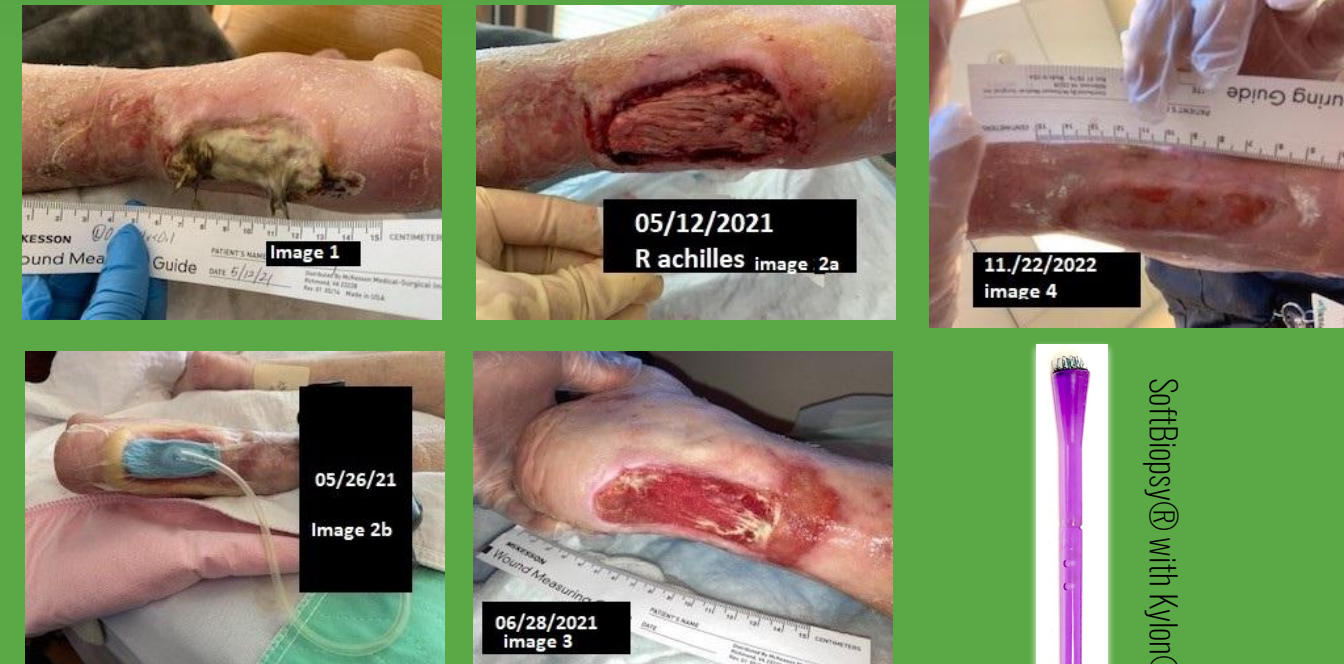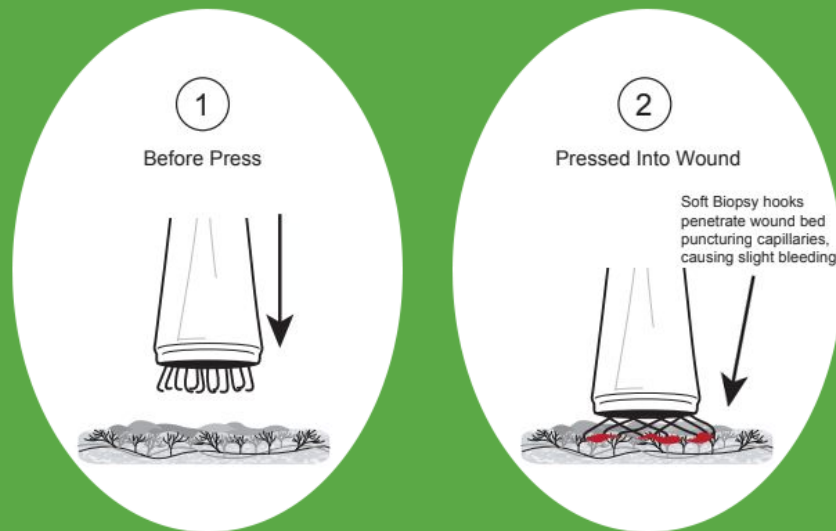
Chronic non-healing dermal ulcers are a silent epidemic generating a significant cost burden on the United States healthcare economy, if not globally. Global market valuation for the treatment of chronic dermal ulcers estimates, 3.5 billion in 2021.(1) Normal wound healing physiology progresses seamlessly through four stages: hemostasis, inflammation, proliferation and epithelialization. This physiologic process will typically occur over 2-4 weeks following skin injury depending on the surface area of the wound. A chronic, entropic, wound state ensues when this physiology stalls at the inflammatory phase preventing the wound from entering the proliferation phase where the human myofibroblast elaborates elastin and collagen increasing granulation tissue density with its attendant microcirculation.(2)

It is well known in the dermatologic and aesthetics literature that elastin and collagen density can be induced using an array of microneedles(3-4). Microneedling leads to the release of growth factors forming new collagen and elastin in the papillary dermis. In addition, new capillaries are formed. Neovascularisation and neocollagenesis recapitulate the dermal form (i.e. neodermis) aiding in reduced photoageing and scars of the integument. This procedure is aptly called "percutaneous collagen induction therapy". The fractional delivery of microneedles at a regular depth up to 3mm creates superfine microperforations into the neodermis, stimulating acute phase injury, initiating the body's natural healing physiology.

Furthermore, it has been described that utilizing autologous whole blood as an advanced wound dressing increases healing velocity with proven clinical efficacy.(5) Within this paper the authors propose a translational application of these two methodologies as a novel adjunct for the management of open, chronic dermal ulcers as a practice innovation. Interlacing percutaneous collagen induction therapy with in situ whole blood clot formation describes the m-perforation methodology.


## Methods

Approaching an entropic dermal ulcer, the site is cleansed and prepped using a skin neutral hypochlorous acid solution over a 2 minute dwell time. In a quilted pattern regular, consistent microperforations are created within the wound base using a 25G hypodermic needle or stamping a **Kylon® hook array of on average 25 evenly (1 mm) separated sickle-hooks mounted on a round, convex applicator platform tip(6)**, encompassing granulation tissue, bone and facial structures if present. Micropunctate bleeding occurs and an in situ autologous whole blood clot is allowed to form in the wound base. Extracellular matrix devices or cellular based tissue products may be applied per their respective indications for use following clot formation. Standard secondary dressings in accordance with wound exudate and the appropriate weartimes are applied. This procedure is repeated weekly until a confluent layer of epithelial cells develops. (Figure 1)



## Case Study

96 yo elder female with atrial fibrillation, atherosclerosis of the lower extremity, venous stasis dermatitis, and non-insulin dependent, Type 2 diabetes mellitus, presented to wound clinic from her skilled nursing facility with a nonhealing, medical device related Stage 4 pressure injury at the R Achilles tendon from a wheelchair footrest. The wound was burdened with moist necrosis and she underwent sharp surgical debridement following a percutaneous vascular intervention at the superficial femoral artery with stent placement and a tibialperoneal trunk angioplasty due to multilevel peripheral arterial occlusive disease. (Image 1) She was already taking a statin, baby aspirin and a direct thrombin inhibitor in accordance with the VOYAGER trial protocol. Patient was kept in walking therapy using an AFO during her healing journey, although she was minimally ambulatory outside of these encounters. m-perforation methodology was utilized during subsequent encounters to facilitate granulation tissue formation over the exposed tendon. (Image 2a & 2b) Disposable negative pressure wound therapy over a micronized human placental membrane device was deployed to stimulate granulation formation over these structures. Low level light therapy was also employed to help induce periwound vasculoneogenesis. (Image 3) Serial micro-perforation procedure encounters were employed on a weekly basis to the granulating wound base. The wound progressed through all phases of healing without complication over a total of 30 weeks, which was protracted due to COVID closure delays and missed patient encounters. (image 4). The patient was scheduled to undergo a split thickness skin graft however the wound resurfaced before this procedure ever took place.



SoftBiopsy® with Kylon® hook array tip

## Conclusion

Reduction in utilization costs and increased clinical efficacy should be the two biggest value propositions of any advanced wound care modality or dressing. Micro-perforation with the Kylon® device, coined as m-Perfarray™ offers both due to the large standardized depth array of hook sickles that simultaneously perforate the wound bed also saving procedure time. The cost of a 25G single microneedle is \$0.04 while the Kylon® device SoftBiopsy® averages under \$5.00, and the method shall approximate the cost of a typical E&M code for a wound visit; average \$75. (Physician fee schedule for CPT).

The authors also propose that the aforementioned methodology will improve the bioavailability of extracellular matrix substrates and cellular bases tissue products used for cellular senescence and entropic wound states. Thesis: elaborated whole blood compounds and cytokines of the acute phase following the m-Perfarray™ method will facilitate graft adherence and engraftment.

This technique is tissue preserving and does not require the volume of phlebotomized blood seen with the previously described whole blood advanced wound dressing technique.(5) Additionally this method reduces the removal of viable and proliferating cells that would otherwise be extricated using a sharp, ring, curette.

Further gross studies are required to elucidate the velocity by which neodermal regeneration occurs following deployment. Histology samples with adjunctive spectral imaging capture will accomplish this and will be the authors next venture to further describe this method.

## References

1. Sen C. K. (2019). Human Wounds and Its Burden: An Updated Compendium of Estimates. *Advances in wound care*, 8(2), 39–48. <https://doi.org/10.1089/wound.2019.0946>
2. [https://www.woundsource.com/sites/default/files/whitepapers/using\\_the\\_entropic\\_wound\\_cycle\\_as\\_the\\_basis\\_for\\_making\\_effective\\_treatment\\_choices.pdf](https://www.woundsource.com/sites/default/files/whitepapers/using_the_entropic_wound_cycle_as_the_basis_for_making_effective_treatment_choices.pdf)
3. Bhardwaj, D. (2013). Collagen Induction Therapy With Dermaroller. *Community Based Medical Journal*, 1(1), 35–37. <https://doi.org/10.3329/cbmj.v1i1.13854>
4. <https://onlinelibrary.wiley.com/doi/full/10.1111/exd.12723>
5. [https://reddressmedical.com/wp-content/uploads/2021/04/ActiGraft-Brochure\\_Digital\\_v10.pdf](https://reddressmedical.com/wp-content/uploads/2021/04/ActiGraft-Brochure_Digital_v10.pdf)
6. Winter et al. Fabric-Based Exocervical and Endocervical Biopsy in Comparison with Punch Biopsy and Sharp Curettage, *Journal of Lower Genital Tract Disease* - 2012 Apr; 16(2):80-7

Traci A. Kimball MD CWSP<sup>1</sup> and Neal Lonky MD MPH<sup>2</sup>  
WISH Expert Consulting LLP<sup>1</sup>, Histologics<sup>2</sup>