



A Novel Approach to Sickle Cell Leg Ulcer Treatment with the First Human Keratin Graft

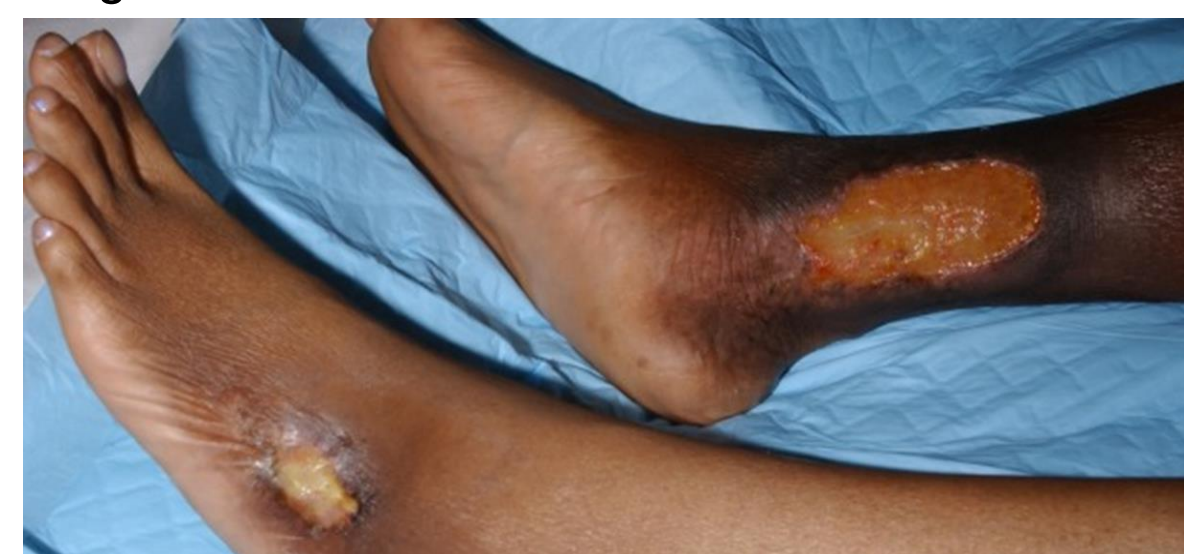Walaya Methodius-Rayford MD, MBA, CWSP¹, Theresa M. Boyer, MS, MSPH², Thomas E. Serena MD FACS² Allison Ramey-Ward, PhD^{SEP}, Sharon Smart, James Poindexter MD, FACS

1. Georgia Vascular Specialist Atlanta, GA, 2. SerenaGroup Research Foundation Cambridge, MA
ProgenaCare Global, LLC. Marietta, GA, USA 30067



Introduction

Sickle cell leg ulcers (SCLUs) are a painful, recurring, and often severe complication of sickle cell disease. Geographical variability exists in the prevalence of SCLUs with the burden ranging from 14% in the United States to as high as 40% in tropical countries, such as Jamaica [1,2]. Known risk factors for SCLUs encompass demographic characteristics including age > 20 years and male sex. There is a noted association with patient genotype, and homozygous individuals are more likely to be affected [3]. The pathophysiology of SCLUs is multifactorial involving nitric oxide deficiency, vascular intimal hyperplasia, and vascular smooth cell proliferation [4]. This complex pathophysiology contributes to the challenges of comprehensive wound healing in these cases.

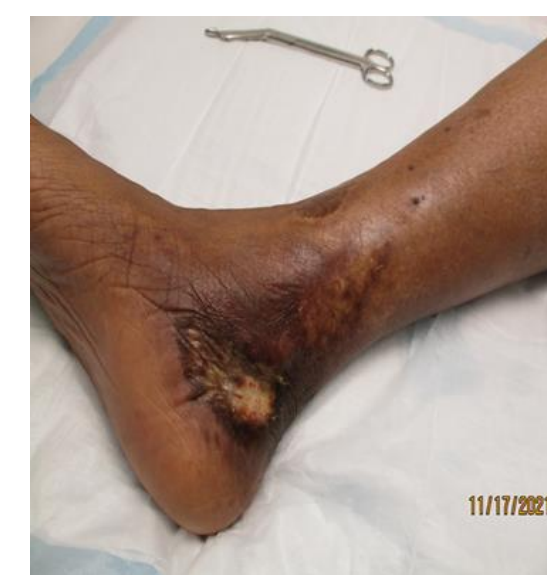

Case

We present a case of a 40-year-old African American female with a > 2-month history of right medial ankle SCLU. The patient reported a long-standing history of slow healing SCLU with 2 other previous ulcers taking > 6-months to heal. She had previously been treated with local wound care, compression therapy, past skin substitutes, and formal split thickness skin grafts.

She reported unbearable pain accompanied by recurrent infection and the need for frequent antibiotics. Her history was notable for chronic venous insufficiency, iliac vein compression treated with stents, and venous ablation. Complete vascular assessment revealed no noted recanalization of the great saphenous vein. She had mild edema but wore compression stockings daily. She had no evidence of PAD but was tired of the pain and considered amputation for relief.

Treatment



Progena matrix is the first human keratin graft for the treatment of chronic. Comprised of human hair, this keratin matrix graft is easily applied to wound base and secured to promote wound healing. The graft promotes wound healing by activation of keratinocytes.

The graft was fixated with steri strips, covered with oil emulsion dressing and hydrogel, and an appropriate secondary dressing was applied. Moisture control bandages were placed as needed for drainage. Compression was applied to the limb at 30-40 mmHg. Due to extensive stasis dermatitis, the surrounding skin was protected with zinc oxide. Wound dressings were changed, and a new graft was placed once weekly.

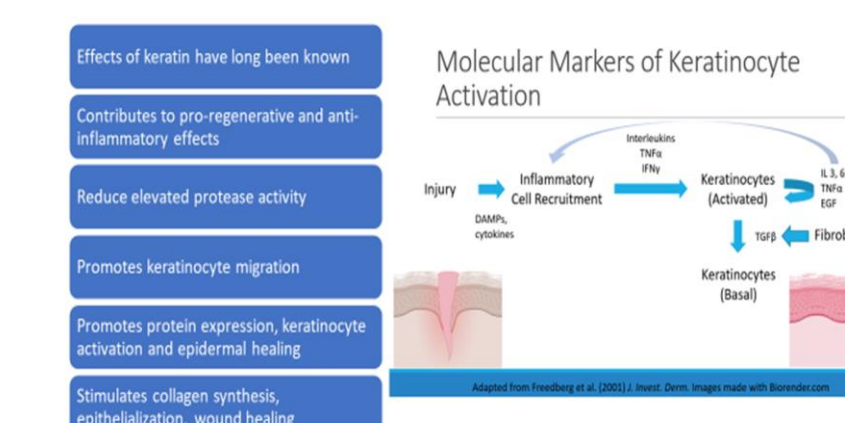


Clinical Significance

This case illustrates the use of a human keratin graft to improve and accelerate healing of SCLUs. Chronic non-healing wounds such as SCLUs are complicated by infection, necrosis², chronic pain, and deformity making them high risk wounds for unfavorable outcomes such as amputation. Human keratin in the wound care space is not new to wound healing, known for its promotion of re-epithelialization, pro-regeneration and anti-inflammatory effects, barrier protection, acceleration of wound healing. We present the first human keratin graft, Progena Matrix, used to aid and accelerate wound healing.

Keratin is directly associated with the signaling in basal and activated keratinocytes¹. Keratinocyte activation is an important step in the wound healing process. Progena matrix graft activates the keratinocytes to promote wound healing.

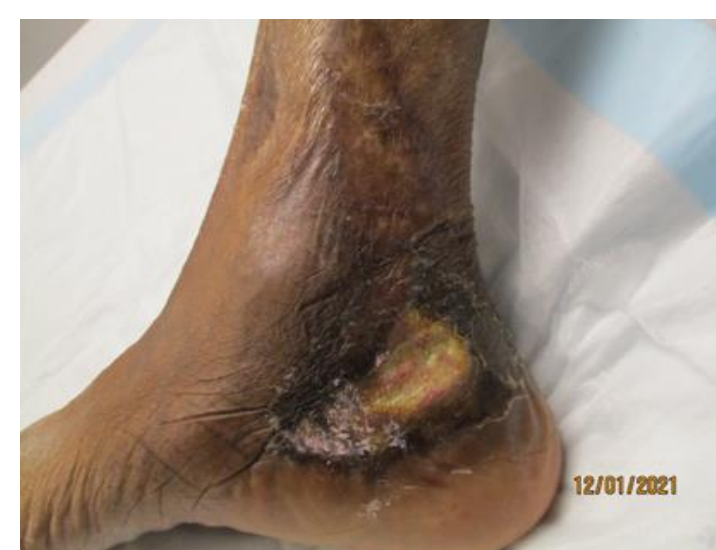Why Keratin to treat wounds



Results

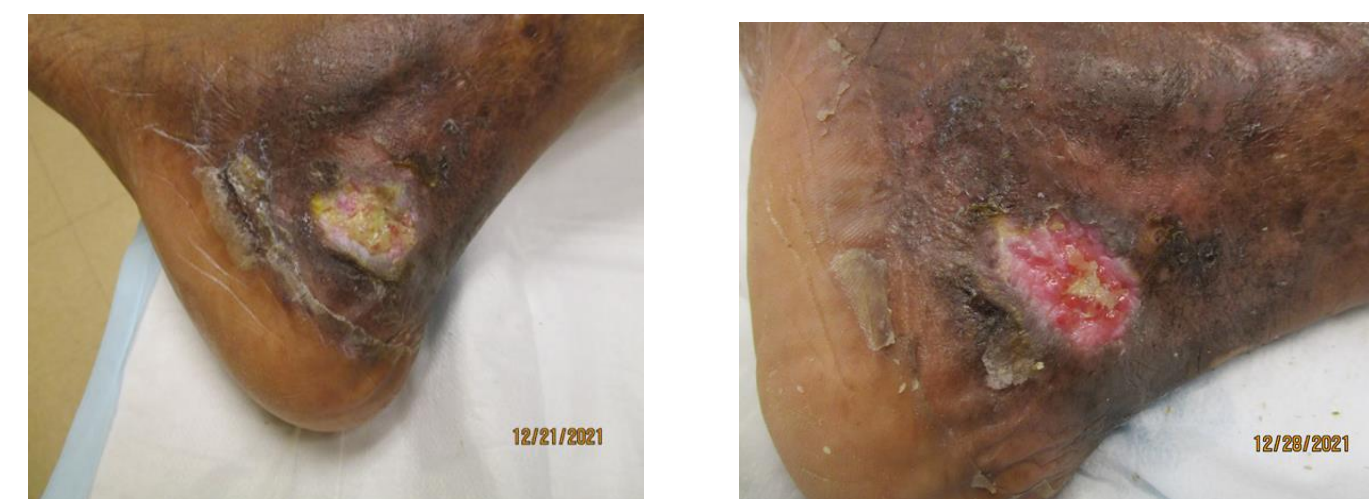Before Treatment

On 12/1/2021, Progena Matrix human keratin graft trial was initiated. The wound measured 1.4 x 2.0 x 0.3 cm. The human keratin graft was fenestrated with an 11-blade scalpel and applied to the wound. There was a small rim of margin overlap of the wound edges.



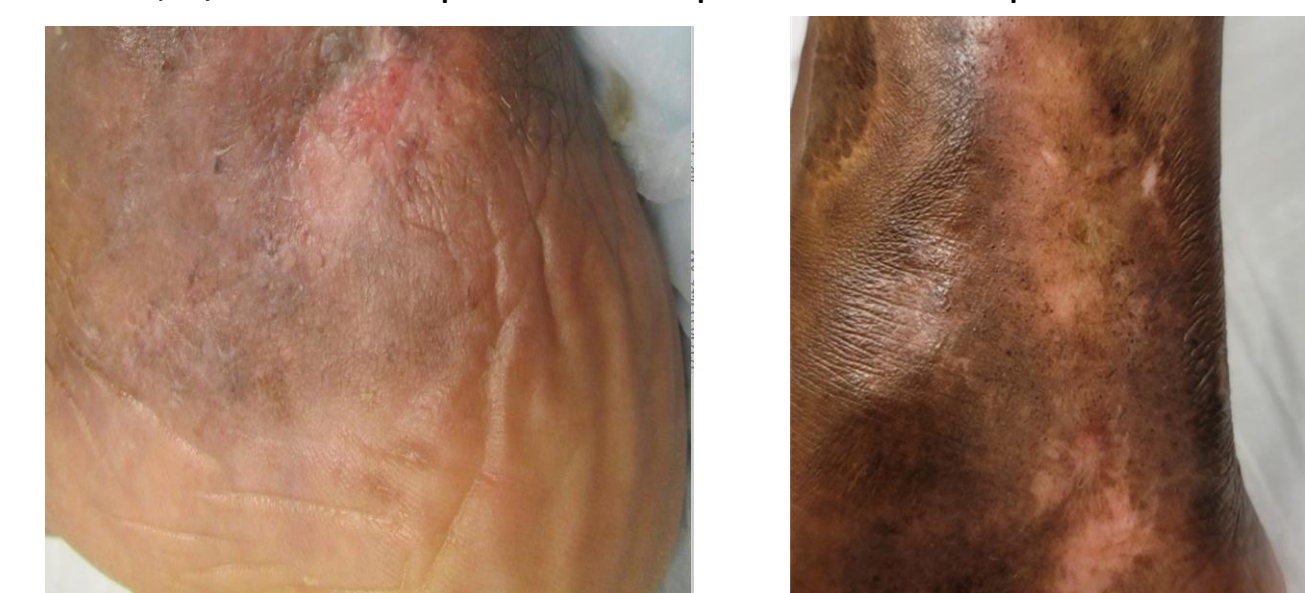Week 4 Results

Improvement to the wound bed and surround could already be appreciated on 12/21/2021. By week 4, 12/28/2021, the wound had decreased in size to 1.2 x 0.8 x 0.1 cm. There was new granulation and epithelialization of the wound at the margins. That patient's stasis dermatitis had resolved.



Week 6 Results

The wound was resolved by week 6, and the site remains closed to date, 8/2022. The patient was spared of an amputation.



References

1. Monfort, J.B. and P. Senet, Leg Ulcers in Sickle-Cell Disease: Treatment Update. Adv Wound Care (New Rochelle), 2020. 9(6): p. 348-356.
2. Powars, D.R., et al., Outcome of sickle cell anemia: a 4-decade observational study of 1056 patients. Medicine (Baltimore), 2005. 84(6): p. 363-376.
3. Altman, I.A., et al., A treatment algorithm to identify therapeutic approaches for leg ulcers in patients with sickle cell disease. Int Wound J, 2016. 13(6): p. 1315-1324.
4. Minniti, C.P., et al., Vasculopathy, inflammation, and blood flow in leg ulcers of patients with sickle cell anemia. Am J Hematol, 2014. 89(1): p. 1-6.