



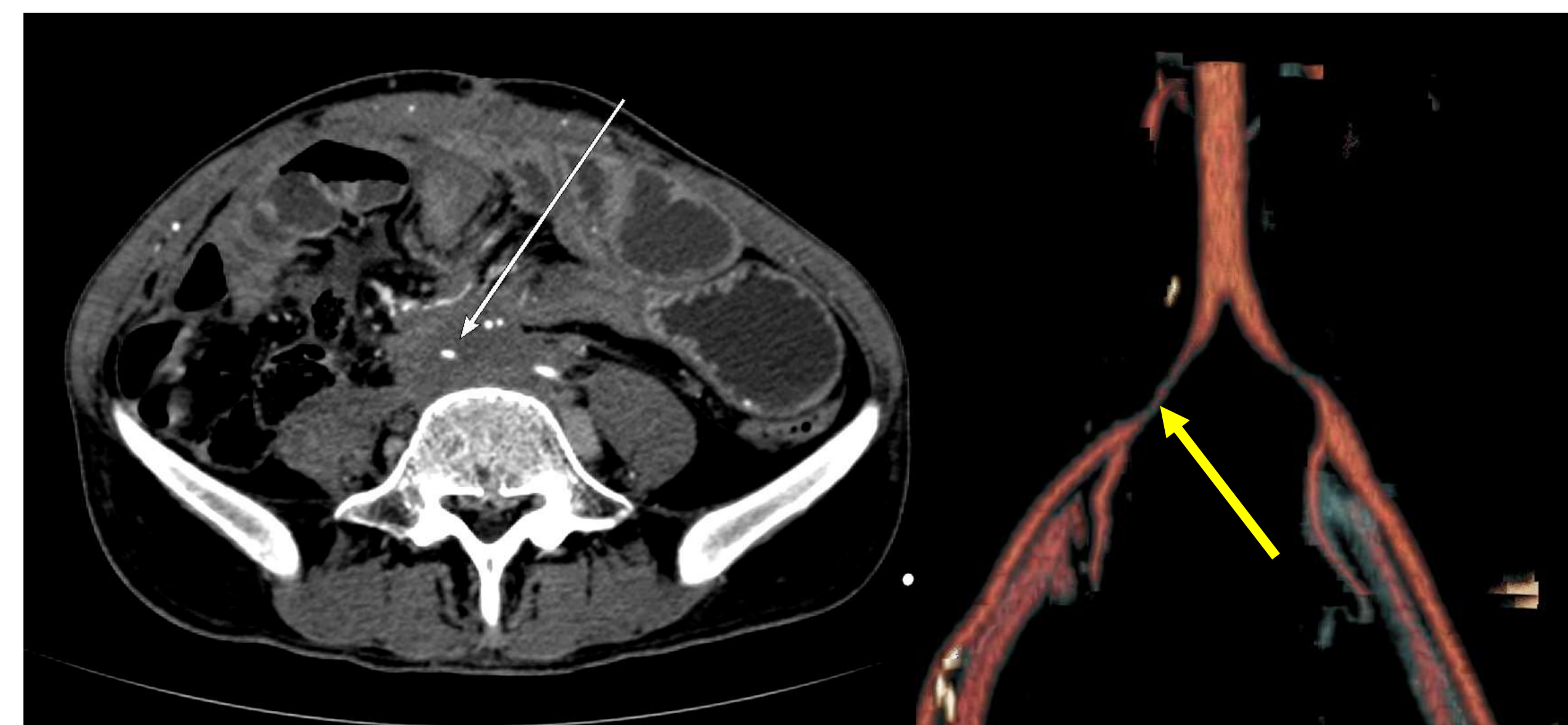
## PURPOSE

- Isolated aneurysm in iliac artery are rare.
- Cases of iatrogenic or post traumatic pseudoaneurysm and their management of common iliac artery are even less common
- We present a rare case of iatrogenic pseudoaneurysm of right common iliac artery and its endovascular management.

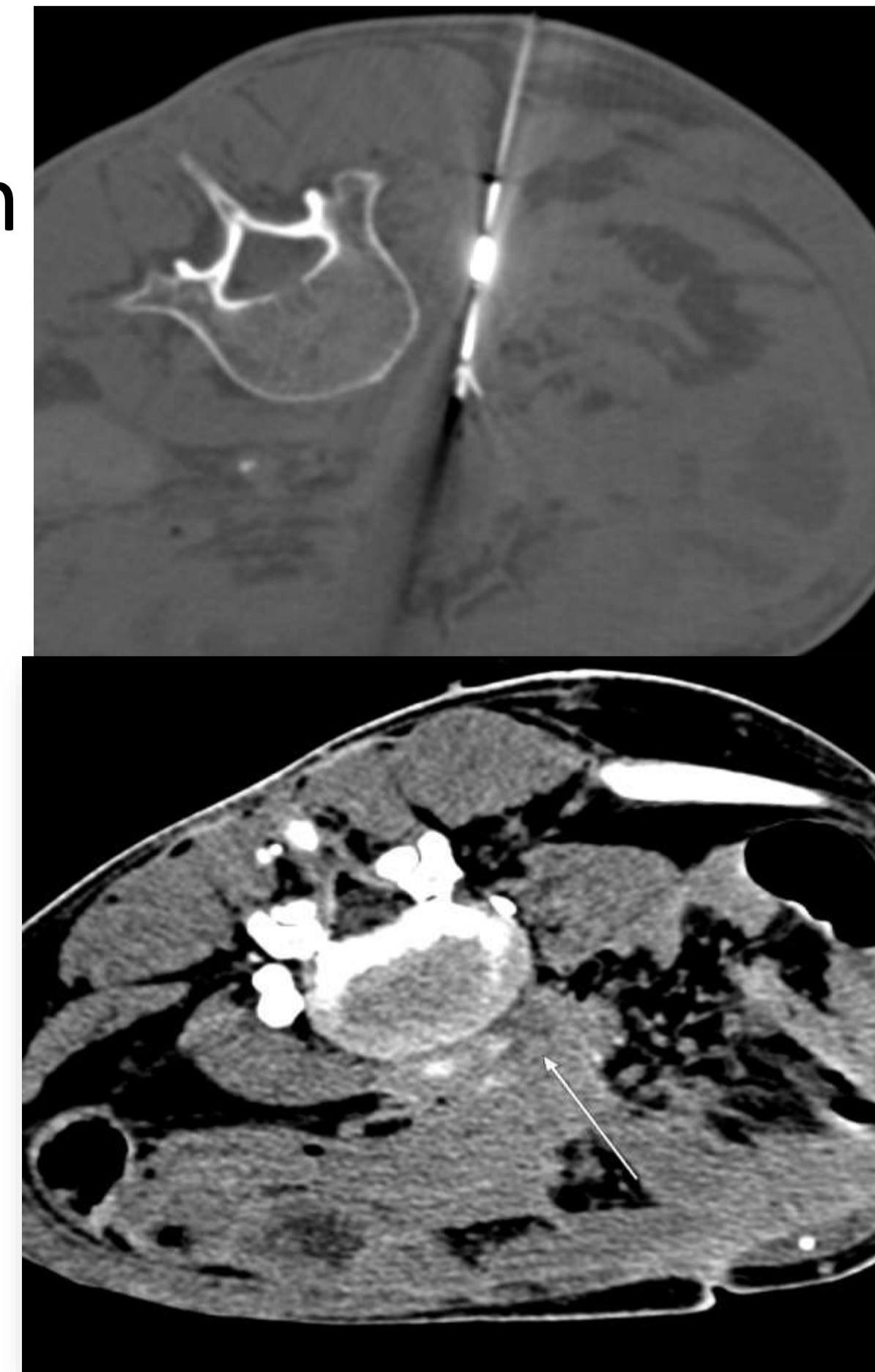
## MATERIALS AND METHODS

A 27 year male patient with recurrent leiomyosarcoma of retroperitoneum presented with right limb severe Claudication

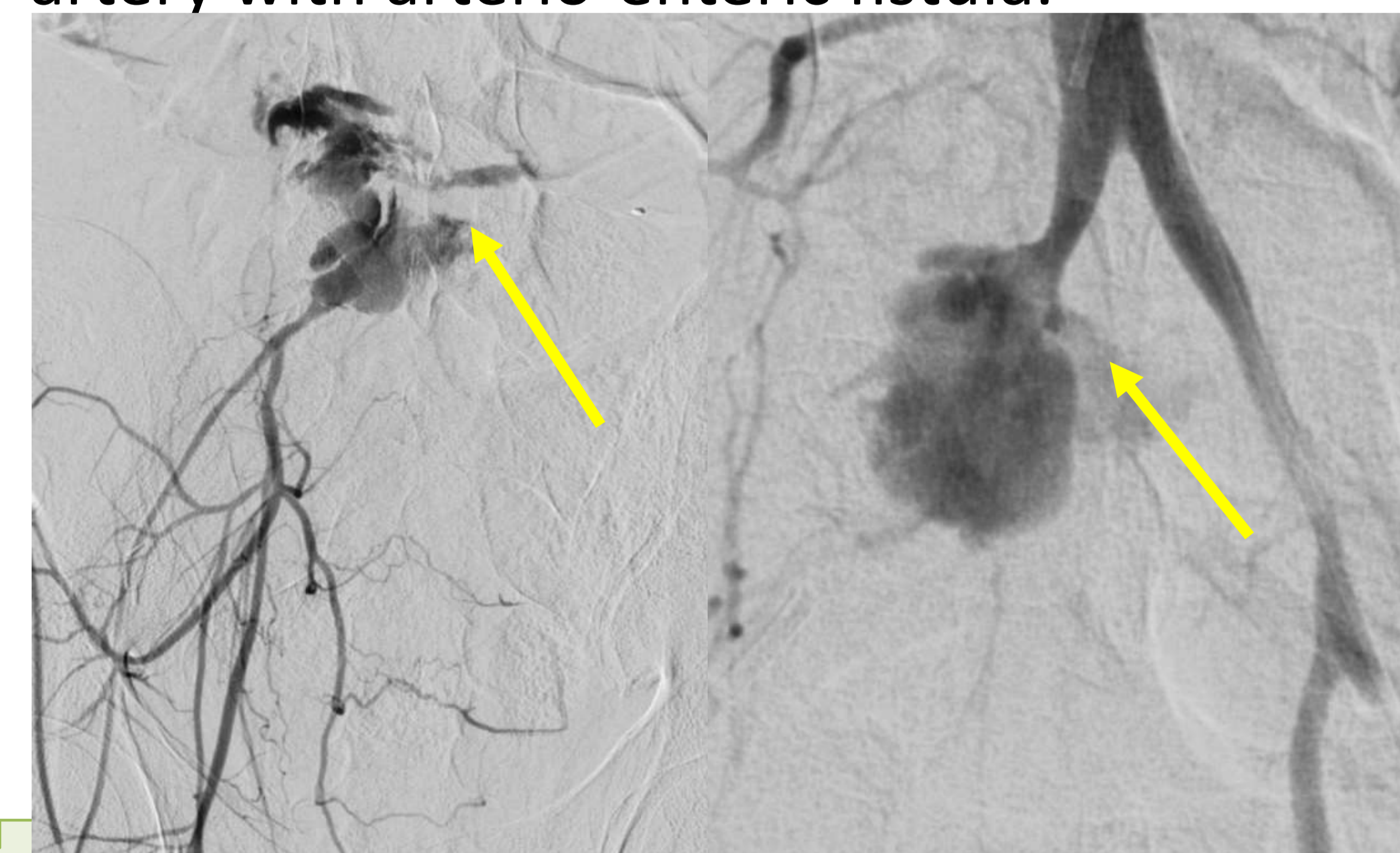CT angiography showed severe narrowing of the right common iliac artery( White and Yellow arrow) due to recurrent soft tissue mass in the retroperitoneum.



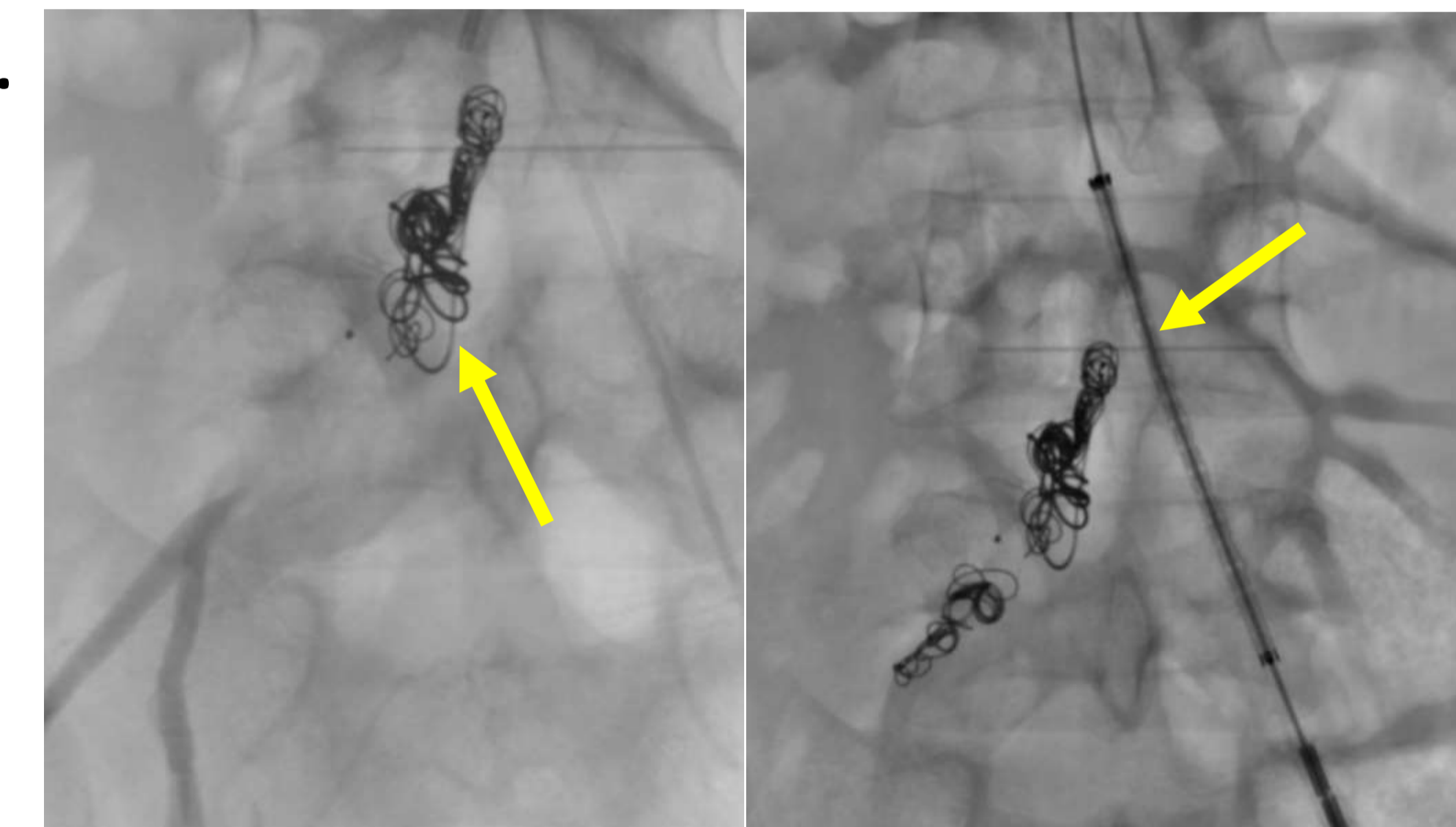
Patient underwent radiofrequency ablation of recurrent soft tissue surrounding the right common iliac artery to relieve external compression on artery. Post ablation showed ablation of soft tissue.



The procedure was uneventful. After 7 days of the procedure patient presented with massive hematemesis and cardiovascular collapse. Angiography showed a large pseudoaneurysm of the right common iliac artery with arterio-enteric fistula.

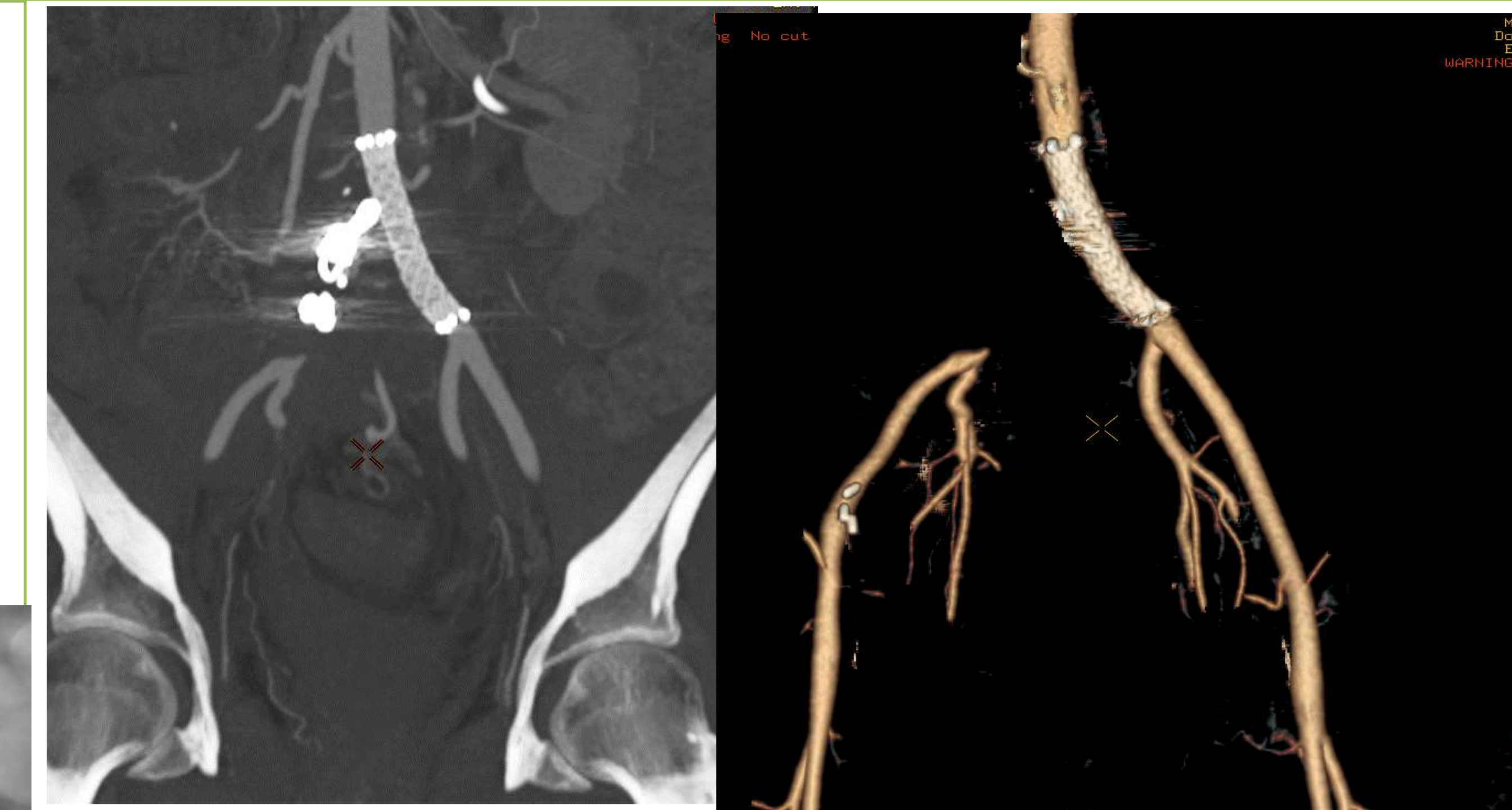
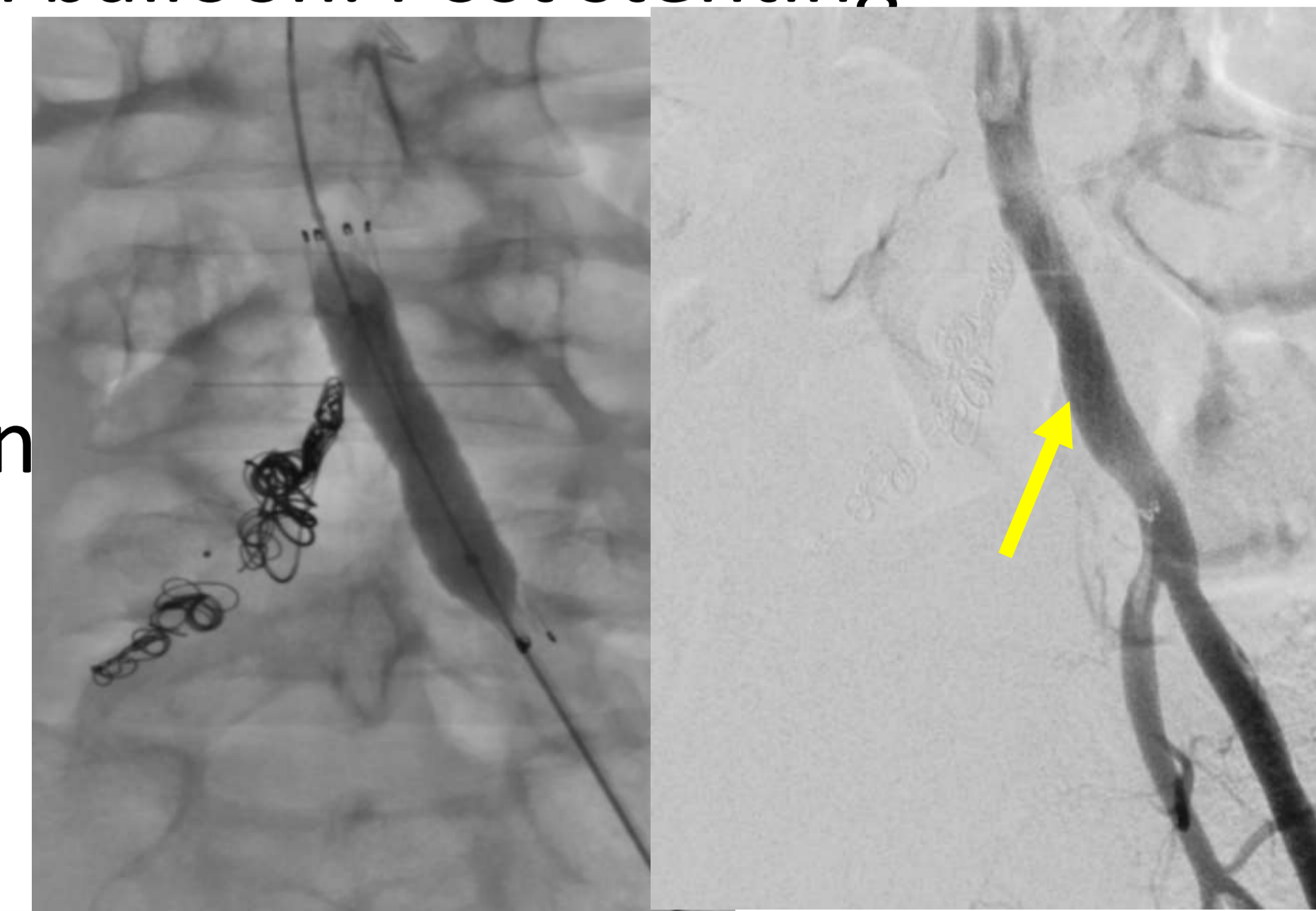
Due to ongoing bleeding and unstable hemodynamic condition of patient it was decided to embolize the right common iliac artery with placement of covered stent from aorta to Left common iliac artery covering the opening of right common iliac artery.



The pseudoaneurysm was embolized using multiple interlock coils and vascular plug with placement of covered 8x60 mm stent on left side to cover origin of right common iliac artery. The vascular graft was dilated using 8 mm balloon. Post stenting

Angiogram Showed Complete Obliteration Of the Pseudoaneurysm.



Post procedure CT angiography showed complete obliteration of the pseudoaneurysm. The distal right external iliac and Internal iliac artery were filling with collaterals. Immediately after the Procedure patient's hemodynamic conditions were improved and inotropes requirement was decreased. Patient was extubated after 1 day and discharge in stable conditions after 7 days.

## CONCLUSION

Intragenic pseudoaneurysm of the iliac arteries are potentially fatal and early diagnosis and management are important. Endovascular repair with covered stents are treatment of choice whenever feasible. This Close follow up of patients after ablation near the major arteries are utmost important.