

A Unique Technique for Management of Challenging Surgical Wounds: Treatment of a Thoracic Wound Complication with a Transforming Powder Dressing (TPD)

Rosalyn Barnabee, BSN, RN, WOC; Tammy Jensen Lichtman, RN, BSN, CWON; AdventHealth Medical Group; Orlando, FL
SAWC Fall 2022 Meeting, Las Vegas, NV | October 13-16, 2022

BACKGROUND

Traditional standard of care (SOC) management of surgical wounds involves conventional dressing applications or negative pressure wound therapy (NPWT) to accelerate wound healing.¹ Current SOC, however, is limited in treating complex surgical wounds. NPWT can be painful and difficult to apply in certain anatomical locations.² Conventional dressings require frequent applications and drain medical resources while increasing patient discomfort and exposure to wound contamination.

Alternative treatment modalities must be considered to provide optimal patient care. We present a case study incorporating treatment with Transforming Powder Dressing (TPD*) in a patient with a complicated thoracotomy related wound with a chest tube.

CASE OVERVIEW AND METHODOLOGY

A 34-year-old male with no significant prior medical history was admitted for COVID-19. Hospital course was complicated by pulmonary hemorrhage s/p right thoracotomy, and a subcutaneous hematoma evacuation requiring incision and drainage resulting in a nonhealing right thoracotomy wound. NPWT was utilized unsuccessfully (hard to get a proper seal) due to the presence of a nearby chest tube.

Patient reported pain (VAS 5/10) at the wound site, worsening with dressing changes. The clinical goal was to expedite wound healing so that he could be evaluated for a lung transplant, and to reduce overall pain and number of dressing changes.

NPWT was discontinued and treatment with a novel wound technology, TPD, was initiated in conjunction with antimicrobial therapy to manage the wound.

TPD is comprised primarily of biocompatible polymers. Upon hydration with saline, TPD granules aggregate to form a moist, oxygen-permeable matrix that protects the wound from contamination while helping to manage excess exudate through vapor transpiration. Once applied, TPD may be left in place for up to 30 days and more powder may be added as needed without requiring full dressing changes. Simple secondary dressings may be used in areas of high exudation or friction. TPD dries and flakes off as the wound heals.

*Altrazeal® Transforming Powder Dressing (USA).

CHALLENGES AND TPD TREATMENT

Challenges and Prior Treatment:

- NPWT: Unsuccessful due to location of chest tube in right lung and central line to right jugular; patient was also receiving ECMO
- Lack of mobility
- Necrosis to tips of fingers and toes
- Unable to lay in bed
- Required assistance to elevate arm for dressing changes

Patient- Reported Pain:

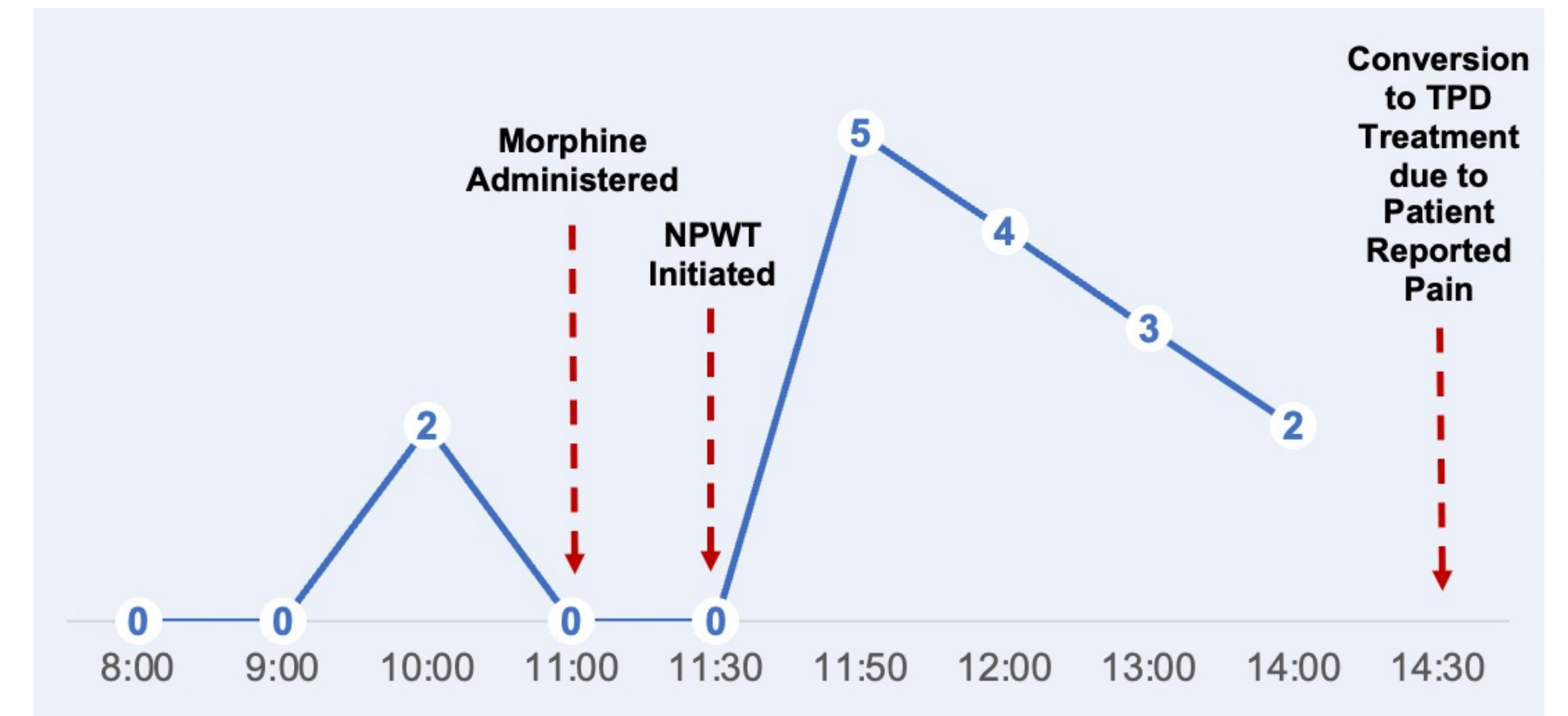
- Pain levels of increased intensity after NPWT treatment despite pre-administration of IV morphine
- High-level of patient reported pain (VAS 5/10) immediately after NPWT activation
- Moderate to mild patient reported pain (VAS 2/10 to 4/10) continued post NPWT treatment
- Patient reported pain compounded by inability to maintain seal with NPWT

TPD Treatment:

- NPWT discontinued due to disturbance to chest tube system and patient reported pain
- TPD mixed with solution of hypochlorous acid to create a gel-like mixture that was used to fill in the wound and stimulate wound base to promote tissue growth**. A silver hydro fiber rope was used to cover the fenestration as an additional barrier

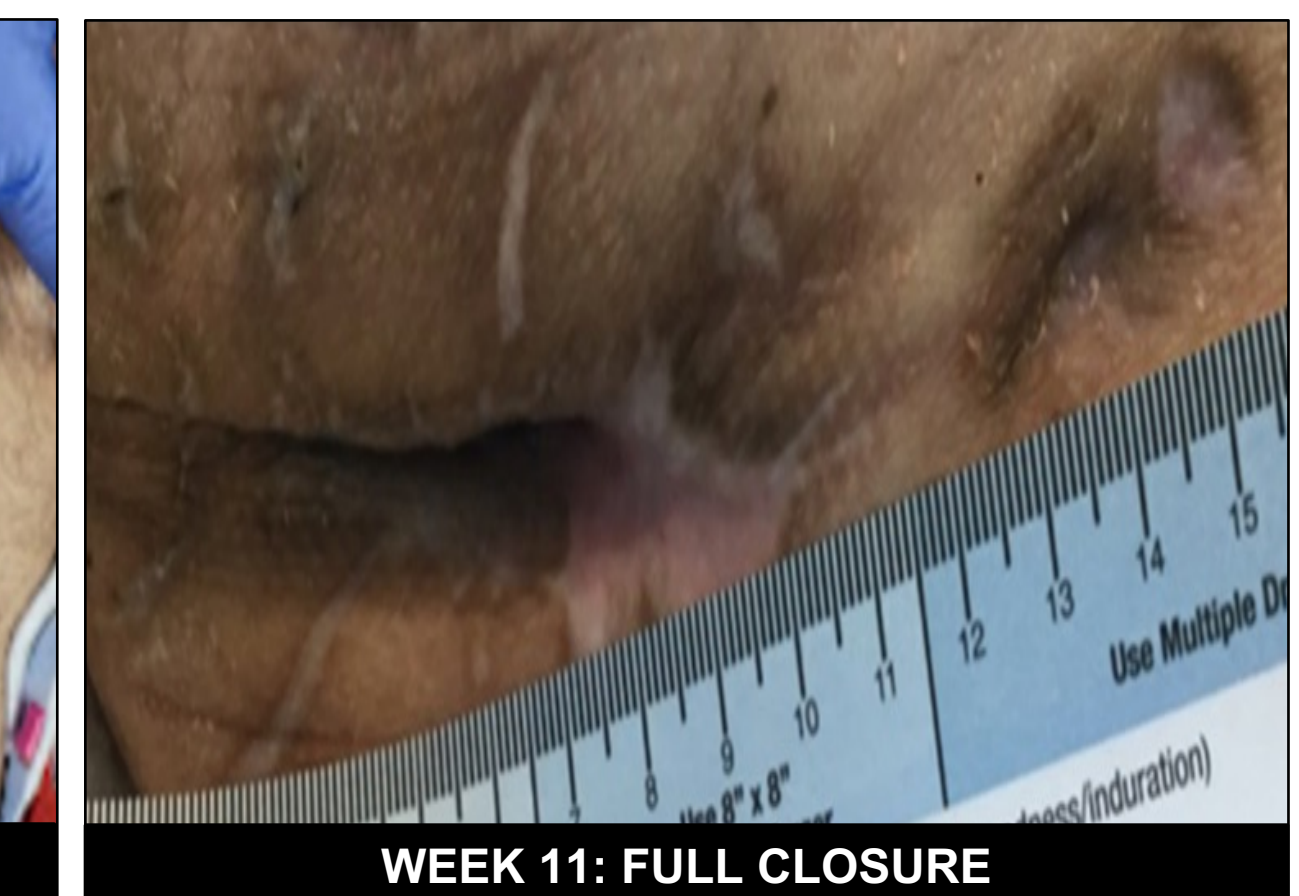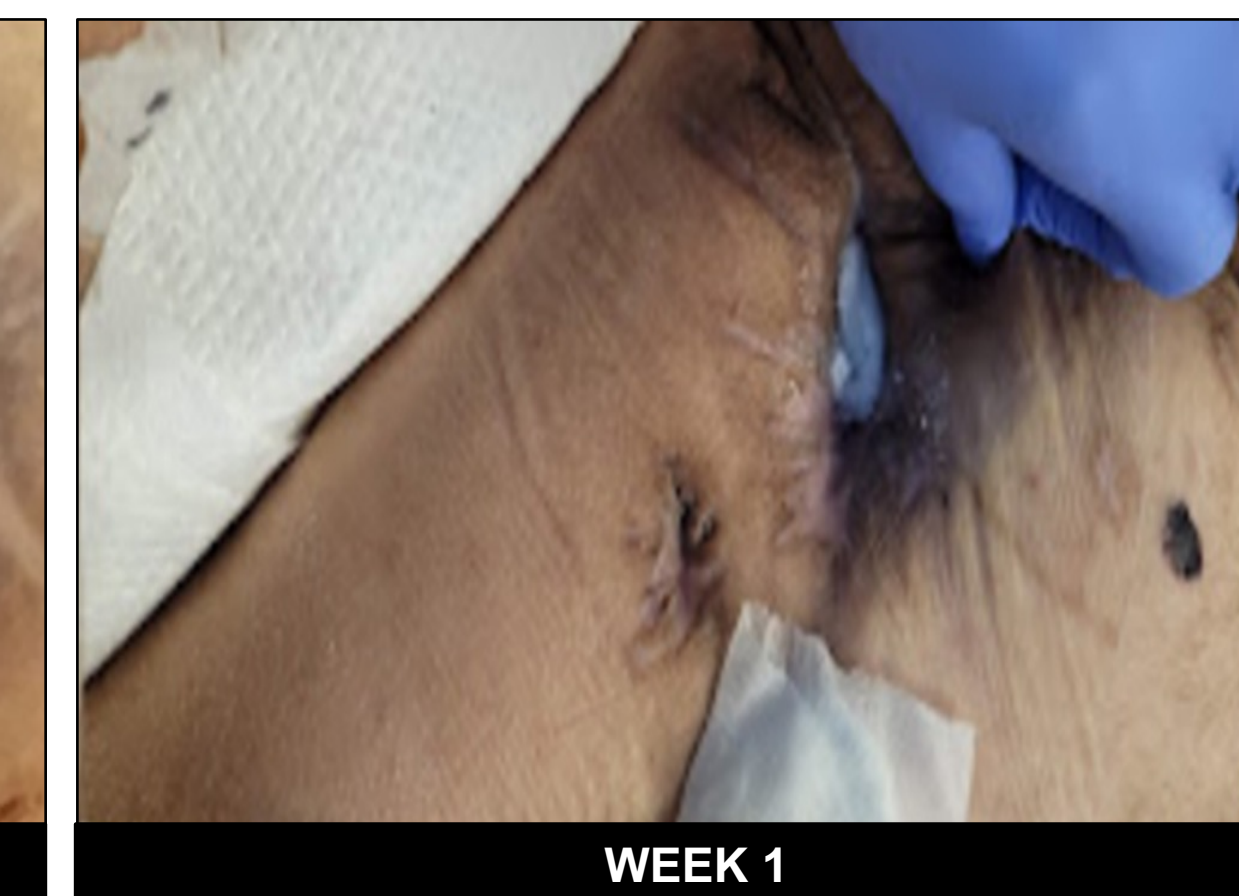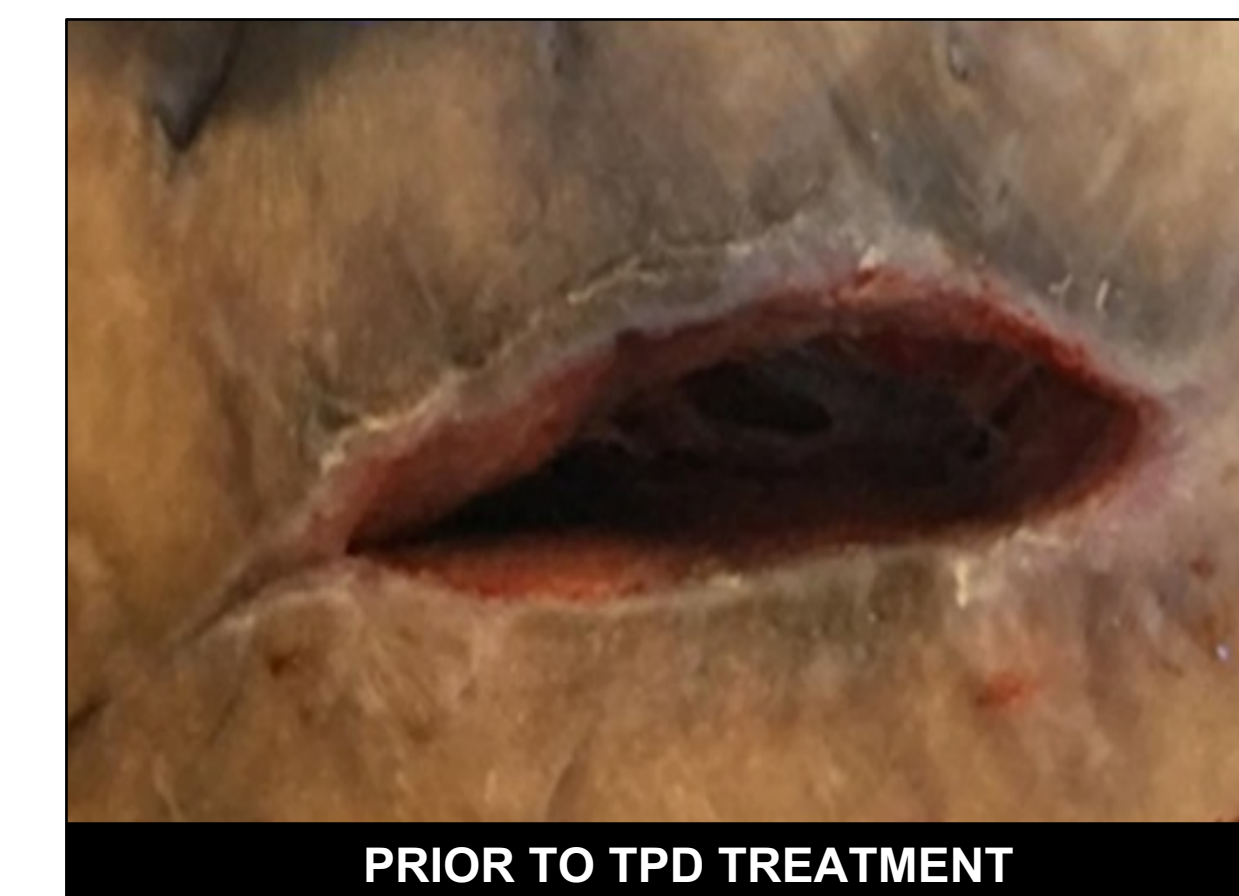**For application instructions and risk of this device refer to Altrazeal Instructions for Use. Altrazeal's intended use is as a hydrogel wound covering without drugs or biologics. Combinations with active agents is considered off-label.

Patient Reported Pain Levels (VAS 0-10): NPWT Treatment



RESULTS

- VAS pain levels reduced to 0/10 post-TPD application
- Discontinued use of morphine and all pain medications
- Reduction in dressing changes due to TPD's extended wear time
 - Enhanced patient comfort while enabling tissue growth
 - Optimized resource utilization due to fewer dressing change requirements and reduced wound assessments
- Week 6: Significant reduction in wound size
- Week 11: Wound closed; patient was transitioned to another hospital for lung transplant



CONCLUSION

Although chest tube insertions are used routinely to drain pleural collections, these invasive procedures are associated with high complication rates (20-40%), including surgical site infections and bleeding, that can occasionally be life threatening.³ SOC treatment, including NPWT, are often problematic in this patient population. Patient comfort and safety are the ultimate priorities in the care of patients with challenging surgical wounds. Alternative treatments must be considered due to the current limitations of SOC.

Based on the clinical observations and outcomes of this case study, we conclude that TPD presents a safe and effective modality for the treatment of challenging surgical wounds, resulting in decreased patient-reported pain and pain medications, improved patient comfort, rapid reduction in wound size and facilitation of wound closure.

REFERENCES

- Harries, R. L., Bosanquet, D. C., & Harding, K. G. (2016). Wound bed preparation: TIME for an update. *International wound journal*, 13 Suppl 3(Suppl 3), 8–14.
 - Upton, D., & Andrews, A. (2015). Pain and trauma in negative pressure wound therapy: a review. *International wound journal*, 12(1), 100–105.
 - Hernandez MC, El Khatib M, Prokop L, Zielinski MD, Aho JM. Complications in tube thoracostomy: Systematic review and meta-analysis. *J Trauma Acute Care Surg.* 2018;85(2):410-416. doi:10.1097/TA.0000000000001840.
- Acknowledgements:** This poster was presented in collaboration with ULURU Inc. All protocols and clinical assessments were conducted independently by AdventHealth without any compensation.