

# Case Report – Bleeding Jejunal Varix: A Disease without Standardized Treatment

John Cooper BS, William Chastant MD, Jeffrey Juneau MD,  
Daniel Raines MD

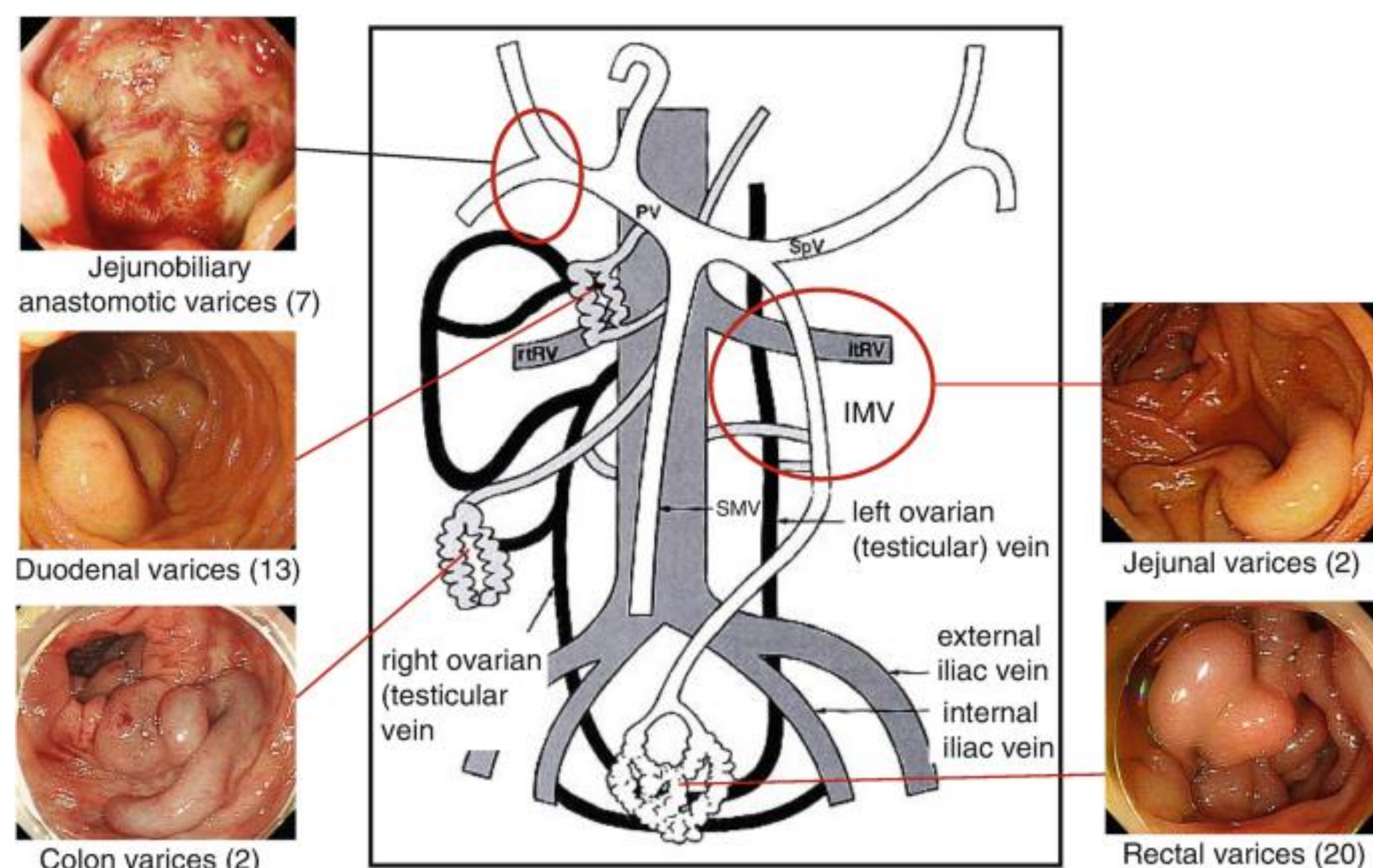
Department of Internal Medicine, Section of Gastroenterology Louisiana State University Health Sciences Center, New Orleans, LA



## Introduction

- Ectopic varices occur within the abdominal viscera, excluding the stomach and esophagus
- Ectopic varices account for 1-5% of all variceal bleeding in the U.S. and Europe
- Most frequent sites include the duodenum and the rectum
- The ileum and jejunum account for 0.3-0.9% of all variceal bleeding in the U.S. and Europe
- Although techniques exist to treat bleeding in these areas, there is limited data on the use of hemostatic clips via double balloon enteroscopy (DBE) in these scenarios.
- Temporary treatments include octreotide, terlipressin, variceal band ligation, cyanoacrylate injections, and argon plasma coagulation (APC)
- Hemostatic clips are rarely used as treatment of ectopic varices

## Ectopic Varices



## History

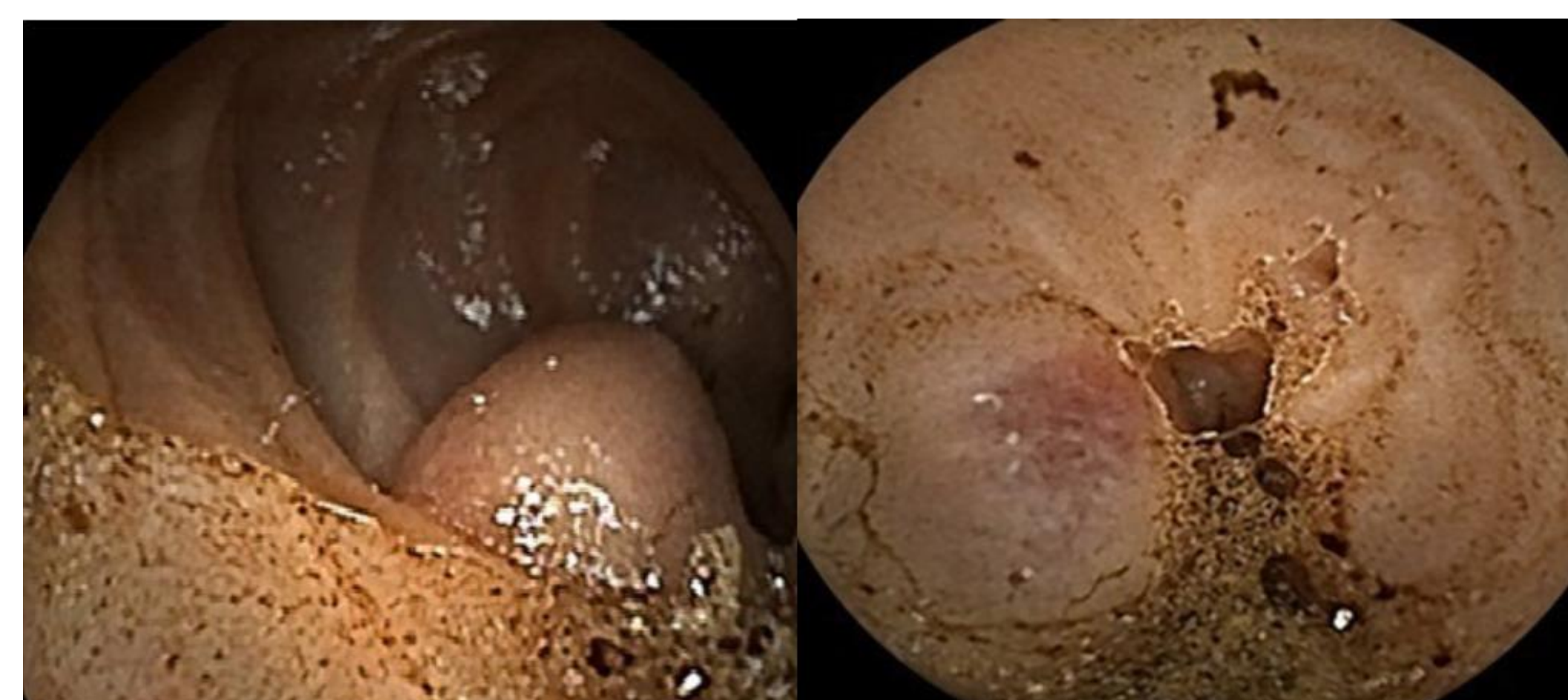- This is a 52-year-old male with three days of hematochezia and near syncope
- PMH: hepatitis C/ alcoholic cirrhosis complicated by esophageal varices status post banding ligation, alcohol and drug use

## Examination

- Vitals: Afebrile with sinus tachycardia
- Physical Exam: AAOx3, distended abdomen with moderate ascites, and trace peripheral edema
- Labs: Hb 5.1, platelets 68, MELD 10
- Abdominal ultrasound: liver cirrhosis and moderate ascites

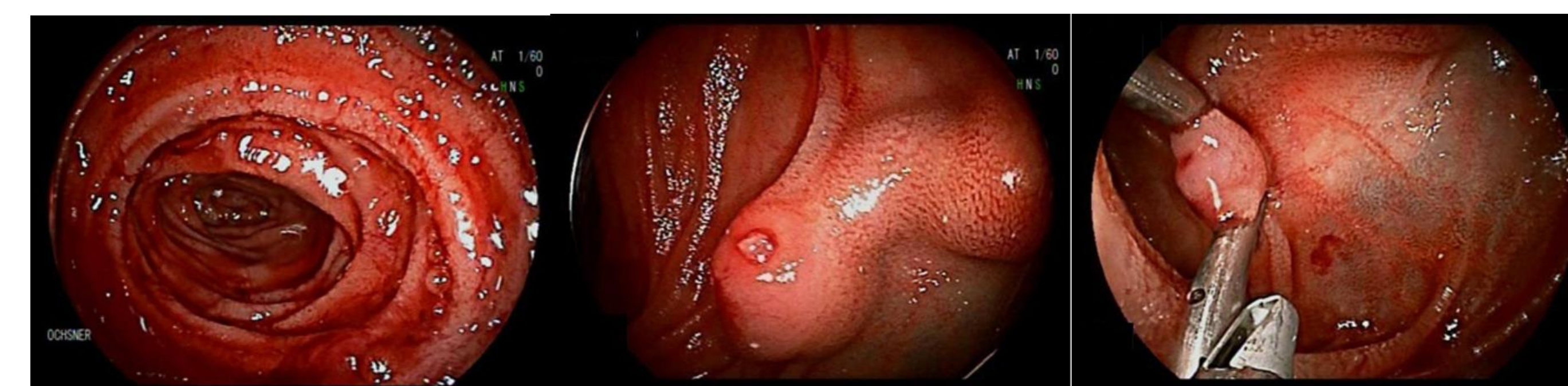
## Management

- Started on ceftriaxone, continuous octreotide, and a daily proton pump inhibitor
- Given pRBC and FFP transfusions as needed
- EGD: small esophageal varices without active bleeding or blood in the esophagus
- Colonoscopy: blood throughout the colon and terminal ileum, no actively bleeding sites
- Video capsule endoscopy: submucosal lesion proximal to the distal jejunum. Mucosa was denuded concerning for ulceration and possible source of bleeding



## DBE Findings

- Retrograde DBE: bright red blood throughout the ileum
- Anterograde DBE: mid-distal jejunum varix with active bleeding from a focal mucosal break and fibrin formation
- Two hemostatic clips were placed on the proximal and distal sides of the bleeding site, and hemostasis was achieved.



- Discharged home on furosemide, spironolactone, lactulose, propranolol
- Scheduled for a balloon-occluded retrograde transvenous obliteration (BRTO) for definitive therapy
- Despite not following up for BRTO, the patient has had no further episodes of bleeding at 6 months following intervention.

## Discussion

- Study reviewing VCE reported 8.1% of patients with cirrhosis had small bowel varices
- Cyanoacrylate injections have been used for small bowel varices in the past but carry some risk of infection and pulmonary embolism
- Our case shows an example of sustained hemostasis via clips without the risk of complications seen with cyanoacrylate injections

1. Birnmoeller KF, Thonke F, Soehendra N. "Endoscopic hemoclip treatment for gastrointestinal bleeding." *Endoscopy* 1993;25:167-70  
 2. Murino A, May A, Lazaridis N, et al. "Double-balloon enteroscopy assisted cyanoacrylate injection therapy of small-bowel varices: international experience from two european centres." *Gut* 2018;67:A35  
 3. Papamorris NE, Matrella E, Blevrakis EG, Kouroumalis EA. Acute pulmonary embolism following N-butyl-cyanoacrylate endoscopic injection sclerotherapy. *Ann Gastroenterol.* 2012;25(3):261.  
 4. Norton ID, Andrews JC, Karmath PS. "Management of Ectopic Varices." *Hepatology*; 1998 Oct; 28(4):1154-8  
 5. Watanabe N, Toyonaga A, Kojima S, Takashimizu S, Ono K, Kokubo S, Nakamura K, Hasumi A, Murashima N, Tajiri T. "Current status of ectopic varices in Japan: Results of a survey by the Japan Society for Portal Hypertension." *Hepatol Res.* 2010 Aug; 40(8):763-76.  
 6. Zhiyong Wang, et al. "Clinical Application Value of Metal Clip in the Treatment of Acute Esophageal and Gastric Variceal Bleeding in Patients with Liver Cirrhosis under Endoscopy". *EC Gastroenterology and Digestive System* 3.2 (2017): 70-76.