

# No Way to Rest Easy with Acute Pancreatitis of a Pancreas Rest

Sohum A. Patwa, MD<sup>1</sup>; Jason Ferreira, MD<sup>1</sup>

<sup>1</sup>Warren Alpert Medical School of Brown University, Providence, RI, USA

## Introduction

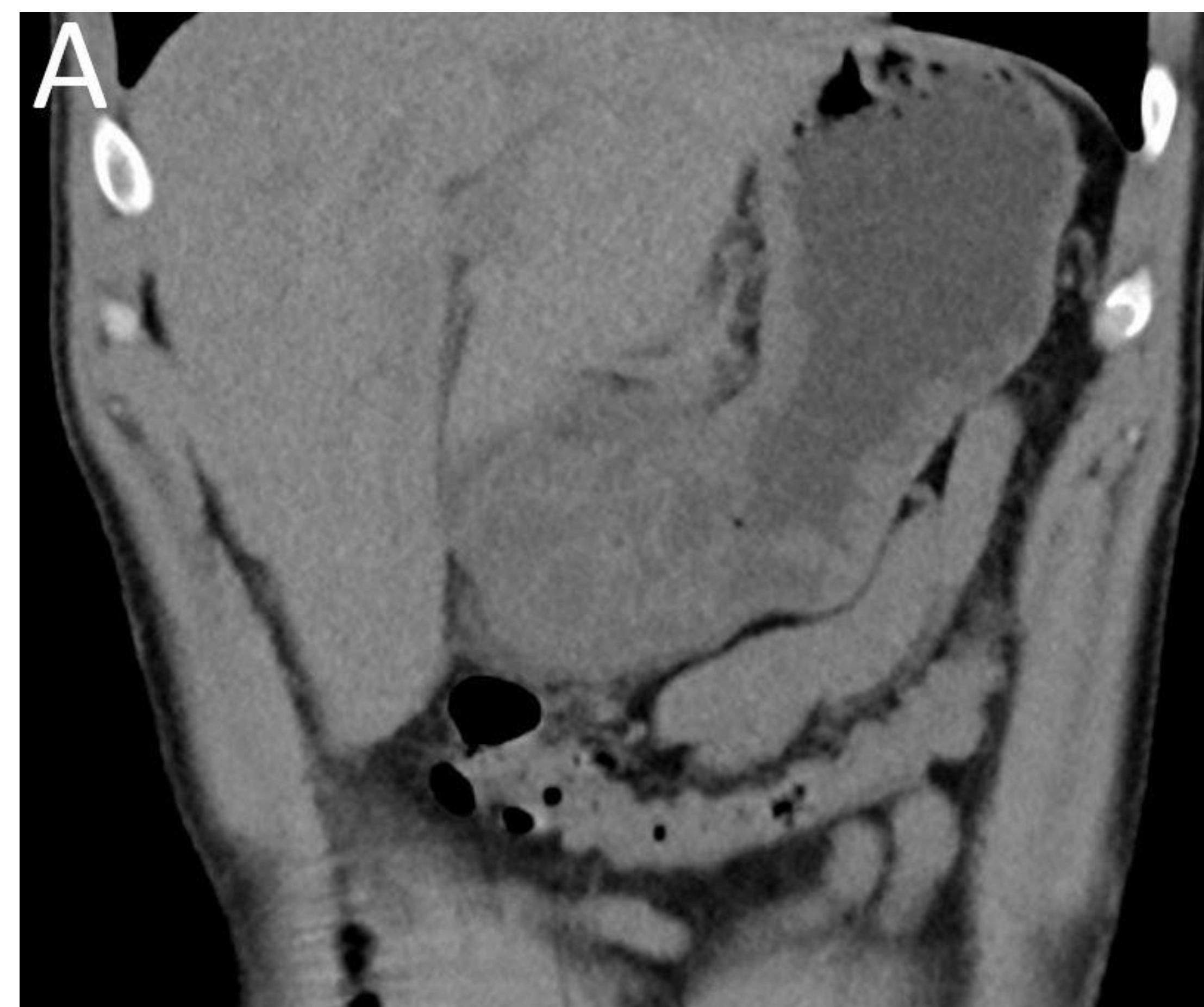Ectopic pancreas tissue (also known as pancreas rest or heterotopic pancreas) is congenital pancreas tissue occurring outside of the orthotopic pancreas, most commonly in the stomach, duodenum, or jejunum. Ectopic pancreas tissue is generally asymptomatic, and usually discovered incidentally. Acute ectopic pancreatitis occurs uncommonly. Acute ectopic pancreatitis without lipase elevation is an even rarer phenomenon. We report a case of acute pancreatitis of a gastric pancreas rest with a normal lipase requiring esophagogastroduodenoscopy (EGD) for diagnosis.

## Case Description

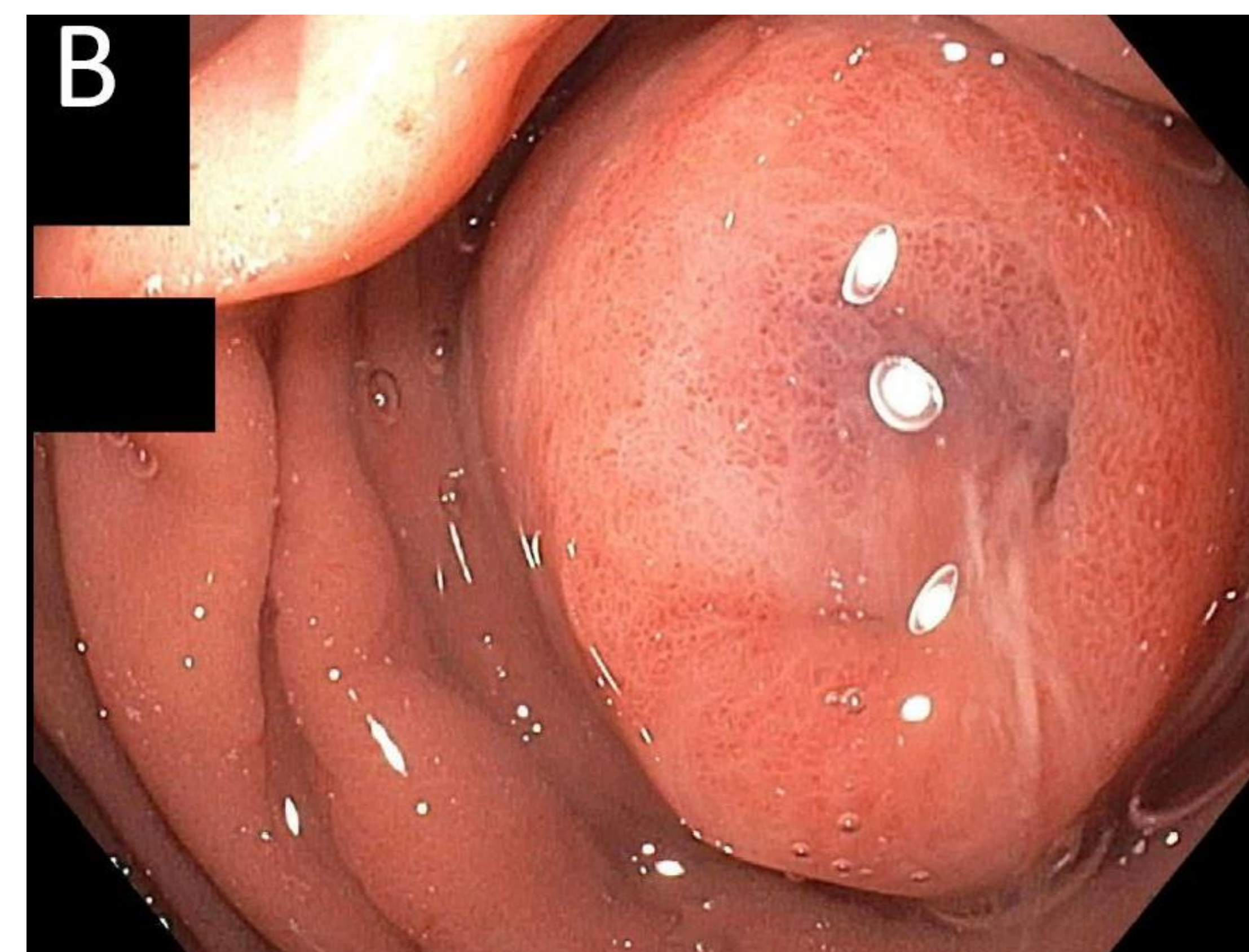
A 42-year-old man with a history of alcohol use disorder presented to the emergency department with a three-day history of severe, sharp, nonradiating epigastric abdominal pain, nausea, and vomiting. His last alcoholic beverage was one week prior to arrival. The patient was mildly tachycardic. Vitals were otherwise stable, and he was afebrile. Physical exam was notable for epigastric tenderness. His labs including lipase were unremarkable.

A CT scan of the abdomen and pelvis revealed marked gastric antral thickening and mild associated inflammatory stranding (Figure 1a). The appearance was concerning for gastritis or peptic ulcer disease; however, an underlying mass could not be excluded. The pancreas was normal in appearance.

The patient then underwent an EGD which demonstrated a single swollen/edematous appearing 25 mm submucosal papule (nodule) with central umbilication in the gastric antrum endoscopically consistent with a pancreas rest (Figure 1b).



**Figure 1A:** CT scan of the abdomen without intravenous contrast demonstrating gastric antral thickening and mild associated inflammatory stranding



**Figure 1B:** EGD demonstrating a single swollen/edematous appearing 25 mm submucosal papule (nodule) with central umbilication in the gastric antrum endoscopically consistent with a pancreas rest

## Patient Course

The patient was diagnosed with acute pancreatitis of a gastric pancreas rest and managed with aggressive intravenous hydration and analgesia.

By the third day of hospitalization, his diet was advanced to solid foods and his pain had improved. His labs remained unremarkable, and he was discharged home.

## Discussion

Acute pancreatitis of a pancreas rest without an elevation in serum lipase level is an exceedingly rare phenomenon.

Acute gastric ectopic pancreatitis must be considered in the differential for antral thickening and can be mistaken on CT imaging for gastritis, peptic ulcer disease, or a mass.

This case highlights the classic endoscopic appearance of an inflamed gastric pancreas rest.

## Conclusion

Early EGD is important in the diagnosis of acute ectopic gastric pancreatitis, especially when encountering a patient with antral thickening and associated fat stranding of unclear etiology on CT.