Gastric Glomus Tumors

Silent Until Ulcerated

Glomus tumors are rare and mostly benign mesenchymal neoplasms comprising fewer than 2% of all soft tissue tumors. They arise from modified smooth muscle cells of the glomus body, an arteriovenous shunt found in peripheral soft tissue of extremities.

Gastric glomus tumors account for 1% of all GI mesenchymal tumors and may appear endoscopically like gastrointestinal stromal tumors (GIST). Diagnosis relies on EGD, histopathologic exam with SMA, vimentin, or mor rarely Syn or CD34 immunohistochemical stain.

46 y/o female previously healthy

Shortness of breath, fatigue, with hemoglobin of 4.4 g/dl

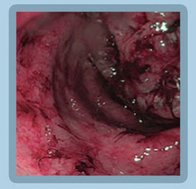

Partially circumferential

72 y/o Female with history breast CA

Hematemesis, melena, and mild midepigastric tenderness

Symptomatic Iron Deficiency Anemia

Esophagogastroduodenoscopy (EGD) showing a large ulcerated gastric antrum mass

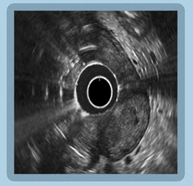

Actively bleeding, EUS showing mass arising from muscularis propria

Metastatic Gastric Glomus

- CT Abdomen showing multiple hepatic massess
- Biopsy with +Smooth Muscle Actin (SMA)

Aborted gastrectomy & hepatectomy due to extent of glomus tumor invasion, undergoing chemotherapy to downsize tumor

TBD

Localized Gastric Glomus

- Fine needle aspirate with +Synaptophysin (Syn)
- Surgical biopsy with +Syn, +SMA

Developed hemorrhagic shock, required emergent exploratory laparotomy and distal gastrectomy

Tumor Free

Lily Kuo, MD, Muhammad Haris, MD, Juan Echavarria, MD, Chandra Umapathy, MD

University Health | UT Health San Antonio