

Introduction

Fistula-in-Ano is a common clinical condition associated with longstanding IBD, but their evolution to adenocarcinoma is rare (1). In such circumstances, a luminal primary tumor is well visualized on colonoscopy and is far more impressive in size than a distal or caudal extension. We present an unusual case of a 74 year old male with long standing perianal fistula and recurrent abscesses presenting with an impressively large friable right gluteal mass with pathology and genomic testing suggestive of a colorectal primary. Astonishingly no colonic or rectal tumor was visualized on colonoscopy.

Case Presentation

A 74 year old Hispanic male with history of Crohn's disease with recurrent perianal fistulas and abscesses, COPD and alcohol dependence presented to the ED after a mechanical fall. He also reported a right gluteal lesion associated with pain and serous discharge for the past two years, which had been increasing in size. On physical exam, he was cachectic and had a foul-smelling fungating, friable mass with overlying granular tissue and serosanguinous drainage (**figure 1**) and palpable bilateral inguinal adenopathy. Laboratory tests revealed leukocytosis with a white count of 15.2K/uL, Hgb 5.5g/dl, MCV 65.5FL, PLT 546K/uL. A Sodium 124mmol/L, Lactic acid 1.2mmol/L and tumor marker workup revealed a CEA 713.6ng/mL and CA 19-9 8.1U/mL. An MRI of the pelvis revealed a 9.8 x 16.1 x 7.7cm heterogenous mass inseparable from the posterior aspect of the anus and along the course of a previously seen perianal fistula (**figure 2**), bilateral inguinal and external iliac lymphadenopathy and multiple pulmonary nodules. Colonoscopy revealed neither colonic mass or fistula track.

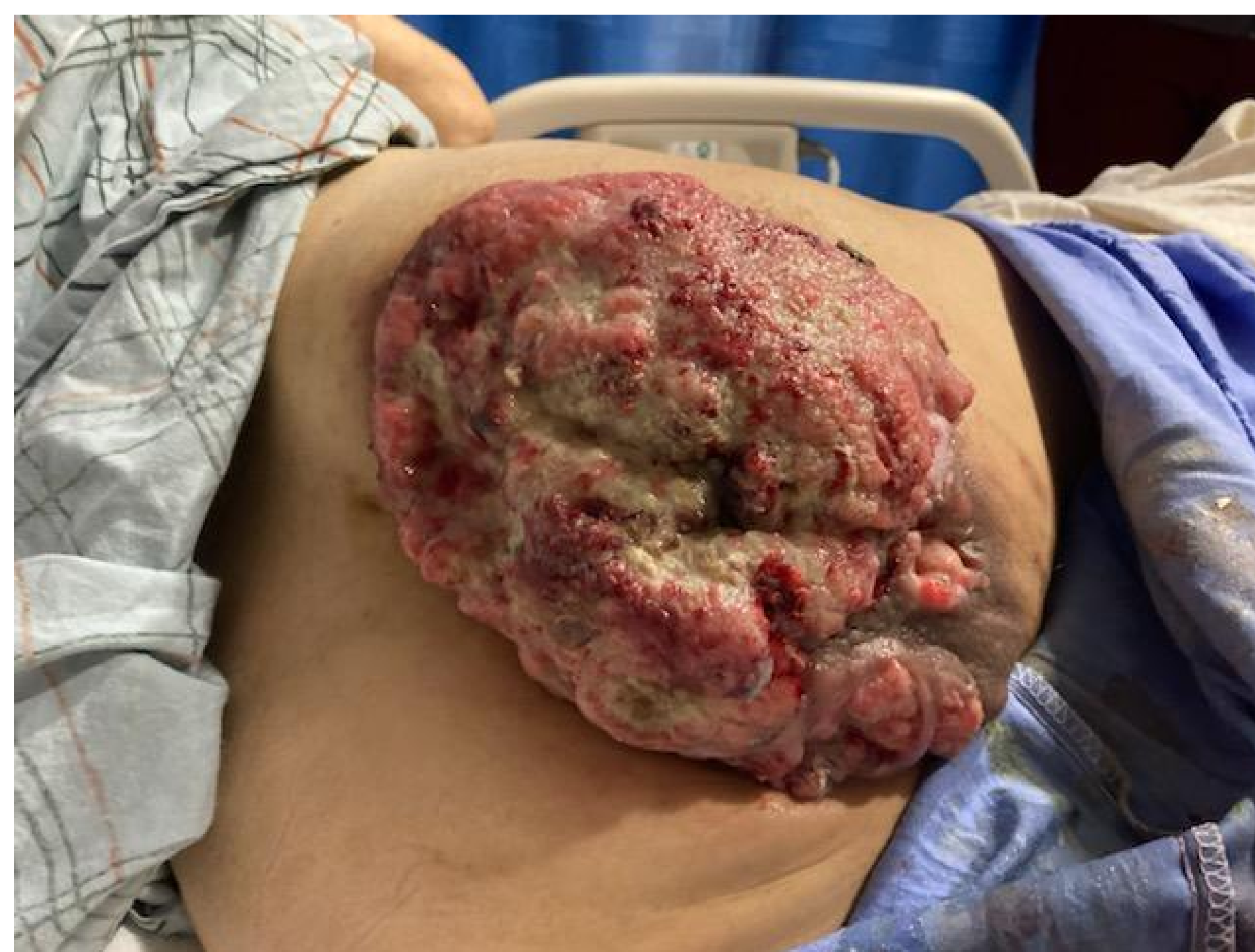

Figure 1. Fungating Gluteal mass

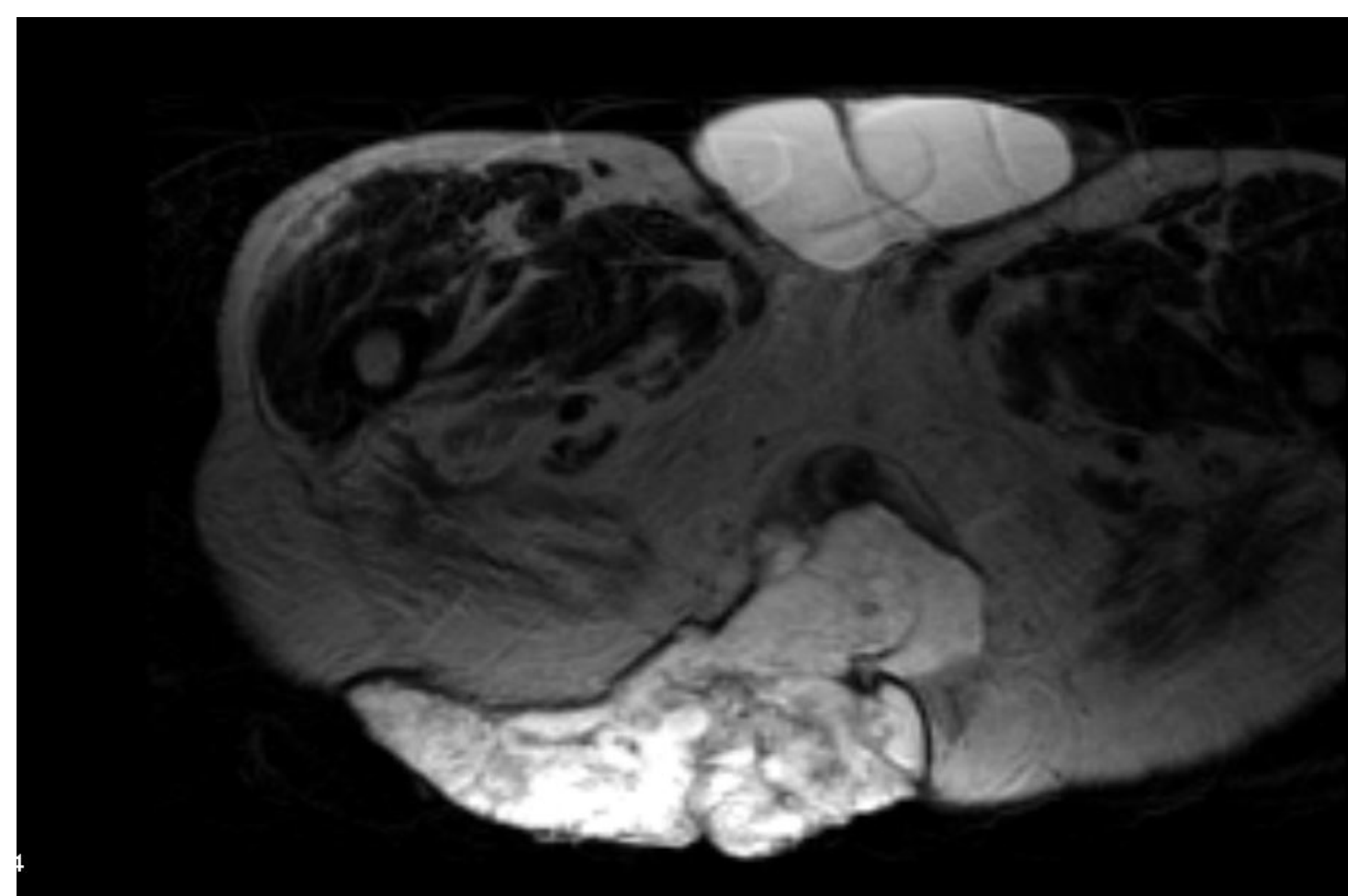


Figure 2. MRI Pelvis w/ & w/out contrast

References

1. Prasad SN., Razik A., Siddiqui F., et al. Mucinous adenocarcinoma arising from chronic perianal fistula mimicking horseshoe abscess. *BMJ Case Rep.* 2018;2018
2. Okada K., Shatari T., Sasaki T., et al. Is histopathological evidence really essential for making a surgical decision about mucinous carcinoma arising in a perianal fistula? Report of a case. *Surg Today.* 2008;38:555-8. doi:10.1007/s00595-007-3651-0
3. Herring CL Jr, Harrelson JM., Scully SP. Metastatic carcinoma to skeletal muscle. A report of 15 patients. *Clin Orthop Relat Res* 1998;355:272-228.

Case Presentation

Punch biopsy of the mass was consistent with a moderately differentiated adenocarcinoma, by immunohistochemistry (IHC) CK-7, CK-20 and CDX-2 were positive, suggestive of a colorectal primary. CancerTYPE ID score was performed which was also most consistent with a colorectal neoplasm. Due to severe blood loss from the surface of the tumor, he received transfusional support and palliative radiation therapy to control bleeding at a hypofractionated dose of 5.0 Gy in 5 fractions. He is currently being treated with palliative chemotherapy consisting of FOLFIRI and bevacizumab with significant decrease in tumor markers and clinical response.

Discussion

Perianal Mucinous Adenocarcinoma (PMA), accounts for 2-3% of all gastrointestinal malignancies and is historically known to arise from perianal abscesses and chronic perianal fistulas(1). PMA has an indolent growth and although metastases to inguinal lymph nodes may be present in advanced cases, distant metastases are rare(2). Differentiation between a primary soft tissue tumor and metastatic disease is difficult without biopsy(3). It was initially unclear whether the chronic perianal fistula previously visualized on imaging was the source of the tumor, especially as colonoscopy did not show luminal involvement and metastatic disease was established. IHC and molecular testing was performed on the biopsy of the gluteal mass, suggesting the site of origin was colorectal in nature. Treatment of malignancy from fistula-in-ano includes surgical resection and/or chemoradiotherapy of primary tumor. In the setting of a metastatic disease in one with a poor performance status, palliative radiotherapy and 5FU-based chemotherapy seems appropriate. Our case highlights the diagnostic value of characterization of tumor by IHC and gene expression in those with metastatic disease on presentation with diagnostic ambiguity.