

## PURPOSE / OBJECTIVES

- Gastrointestinal (GI) manifestations are the most frequently reported extra-pulmonary symptoms of COVID-19 infection with a prevalence of 10%-50%. Most common ones are nausea, vomiting, diarrhea and abdominal pain.
- GI perforation especially spontaneous colonic perforations are rare in the disease course.

## METHODS & CASE

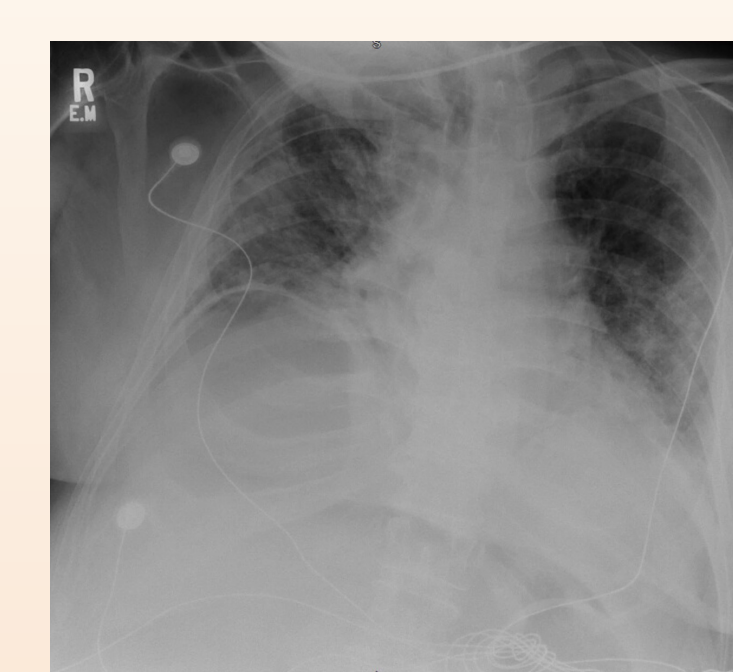
- We report the case of a patient with COVID-19 infection, who developed cecal perforation while recovering from COVID pneumonia, necessitating emergent surgical treatment, and the current literature was reviewed.
- 65-year-old male presented to the hospital with shortness of breath, myalgias and fever. He was admitted to ICU secondary to acute hypoxemic respiratory failure due to COVID 19 pneumonia.
- He was treated with steroids, tocilizumab and remdesivir. On day-11, he developed severe abdominal pain with worsening leukocytosis. His CXR showed air under diaphragm and abdominal. CT showed large pneumoperitoneum, suggestive of a perforated viscus. He underwent emergent laparotomy and was found to have non-obstructive cecal perforation.
- A colonic de-tension and right colectomy with ileo-transverse anastomosis was performed and he was successfully discharged later.
- The tissue pathology showed distended colon, active colitis, transmural granulocytic inflammation, micro-abscesses, and ulceration suggestive of bowel perforation.

## REVIEW OF LITERATURE OF ALL WORLDWIDE CASES OF COVID-19 ASSOCIATED WITH GASTROINTESTINAL PERFORATION

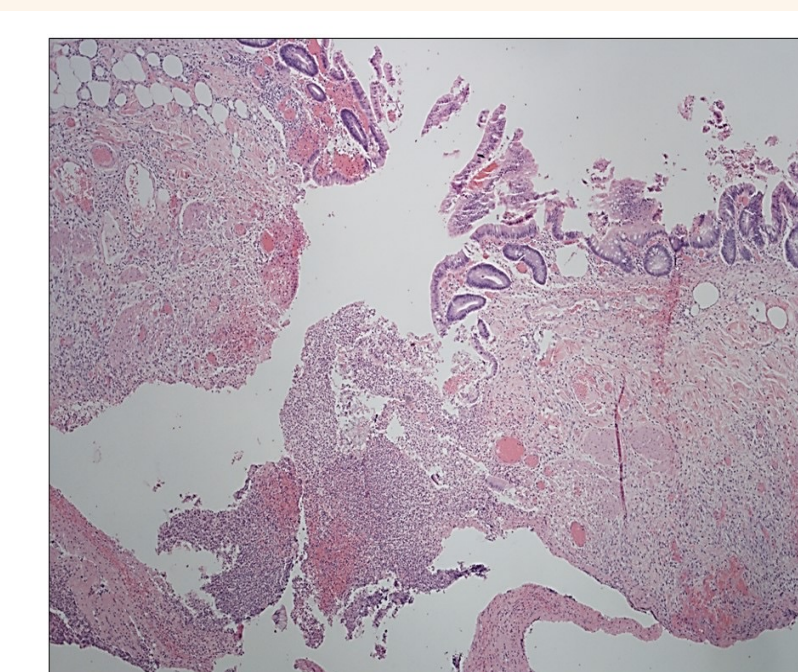
Reference / Author	Study Type	Country	Age in years /Gender	Steroid Usage	Interleukin Inhibitor Usage	GI Perforation Site	Time of GI Perforation	Management	Outcome
Dominguez Prieto et al	Case Report	Spain	74/F	Methylprednisolone	Tocilizumab	Cecum	8th day of admission	Right hemicolectomy with terminal ileostomy	Recovered
Guardiola et al	Case Report	Spain	66/M	Methylprednisolone	Tocilizumab	Cecum	Not mentioned	Right Colectomy	NR
De Nardi et al	Case Report	Italy	53/M	None	Anakinra	Cecum	11th day of admission	Right Colectomy and anastomosis	Recovered
Kangas-Dick et al	Case Report	USA	74/M	Methylprednisolone	NR	NR	5th day of admission	Conservative	Deceased
Argan et al	Case Series	Saudi Arabia	70/M	Methylprednisolone	None	Cecum	44th day of admission	Conservative	Recovered
			37/M	Dexamethasone	None	Cecum	4th day of admission	Conservative	Recovered
			74/M	Methylprednisolone	None	Sigmoid colon	At presentation	Exploratory laparotomy & Hartmann's pouch	Recovered
Galvez et al	Case Report	USA	59/M	Methylprednisolone	Tocilizumab	Gastrojejunostomal anastomosis	5th day of admission	Graham patch repair	Recovered
Poggiali et al	Case Report	Italy	54/F	NR	NR	Diaphragm stomach	At presentation	Surgically, not specified	NR
Correa Neto et al	Case Report	Brazil	80/F	NR	NR	Sigmoid	At presentation	Recto-sigmoidectomy & colostomy	Deceased
Rojo et al	Case Report	Spain	54/F	Methylprednisolone	Tocilizumab	Cecum	15th day of admission	Right colectomy and ileostomy	Deceased
Kuhn et al	Case Report	Germany	59/M	NR	NR	Jejunal diverticulum	At presentation	Small bowel resection and anastomosis	Recovered
Seeliger et al	Case Series	France	31/M	NR	NR	Left colon	At presentation	Left hemicolectomy	Recovered
			82/F	NR	NR	Sigmoid	At presentation	Open drainage	Deceased
			71/F	NR	NR	Gangrenous appendix	At presentation	Appendectomy	Recovered
			80/M	NR	NR	Sigmoiditis	At presentation	Hartmann pouch	Recovered
			77/M	NR	NR	Duodenal ulcer	23rd day of admission	Duodenal exclusion, omega gastro-enteric anastomosis	Deceased
Nahas et al	Case Report	Brazil	92/M	None	None	Transverse colon	Before Admission	Resection	Deceased
Giuffre et al	Case Report	Italy	87/F	None	None	Lower rectum	Before Admission	Conservative	Deceased
Santana et al	Case Report	Brazil	43/M	None	None	Terminal ileum	Before Admission	Resection	Recovered
Costanzi et al	Case Report	Italy	64/M	None	None	Sigmoid	Before Admission	Resection	Recovered
Verma et al	Case Report	Italy	24/F	None	None	Cecum	After Admission	Primary closure and defunctioning ileostomy	Recovered
Balu et al	Case Report	USA	66/M	Dexamethasone	None	Cecum	Before Admission	Resection	Recovered
Verma et al	Case Report	Italy	60/F	Not Specific	None	Upper rectum	Before Admission	Primary closure and defunctioning colostomy	Recovered
Bruce-Hickman et al	Case Report	Singapore	43/M	Hydrocortisone	Tocilizumab	Cecum	After Admission	Resection	NR
Montorfano et al	Case Report	USA	54/F	Dexamethasone	Tocilizumab	Cecum	After Admission	Resection	Recovered
Schwab et al	Case Report	USA	34/M	None	IL-6 inhibitor	Cecum	After Admission	Right hemicolectomy with end ileostomy	Recovered
Giuffre et al	Case Series	Italy	68/F	NR	NR	Rectosigmoid	After Admission	Conservative	NR
			84/F	NR	NR	Rectum	After Admission	Conservative	Deceased
Bhayana et al	Case Report	USA	NR	NR	NR	Ileum	NR	NR	NR
Verma et al	Case Report	Italy	23/M	None	None	Stomach	Before Admission	Primary Closure & grahams patch	Recovered
Kangas et al	Case Report	USA	74/M	None	None	Upper GI	After Admission	Conservative	Deceased
Lee et al	Case Report	Korea	73/M	None	None	Duodenum	After Admission	Primary closure, pyloric exclusion & gastrojejunostomy	Deceased
He et al	Case Report	China	71/M	None	None	Duodenum	After Admission	Primary closure	Recovered
Marcucci et al	Case Report	USA	71/M	None	None	Stomach	After Admission	Surgically, not specified	Deceased
Agnes et al	Case Report	Italy	72/M	None	IL-6 inhibitor	Duodenum	After Admission	Primary closure	Deceased
Tonlari et al	Case Report	Italy	NR	NR	Tocilizumab	NR	After Admission	NR	Recovered
Ranchal et al	Case Report	USA	34/M	NR	Tocilizumab	Cecum	After admission	Right hemicolectomy with end ileostomy	Recovered
Bulte et al	Case Series	Netherlands	58/M	Dexamethasone	Tocilizumab	Cecum	After Admission	Ileocectomy & end-ileostomy	Recovered
			65/M	Prednisolone	None	Rectum	After Admission	Diverting colostomy	Recovered
			57/M	Dexamethasone	Tocilizumab	Transverse colon	After Admission	Extended right hemicolectomy & end ileostomy	Recovered
Munoz et al	Case Report	Colombia	50/M	Dexamethasone	None	Hepatic flexure	After Admission	Enterorrhaphy	Recovered
Our report	Case Report	USA	66/M	Methylprednisolone	Tocilizumab	Cecum	After Admission	Right colectomy & ileotransverse anastomosis	Recovered

Our literature review confirmed only 33 case-reports or series of bowel perforation (either as presenting symptom or during hospital course) in the setting of COVID-19 infection have been reported, with combined 28.5% mortality rate and 5 studies not reporting the outcome. Considering the worldwide incidence of this pandemic, it is a rare complication. **A rare but lethal complication of COVID-19 is GI perforation, especially in setting of treatment with steroids or interleukin inhibitors.**

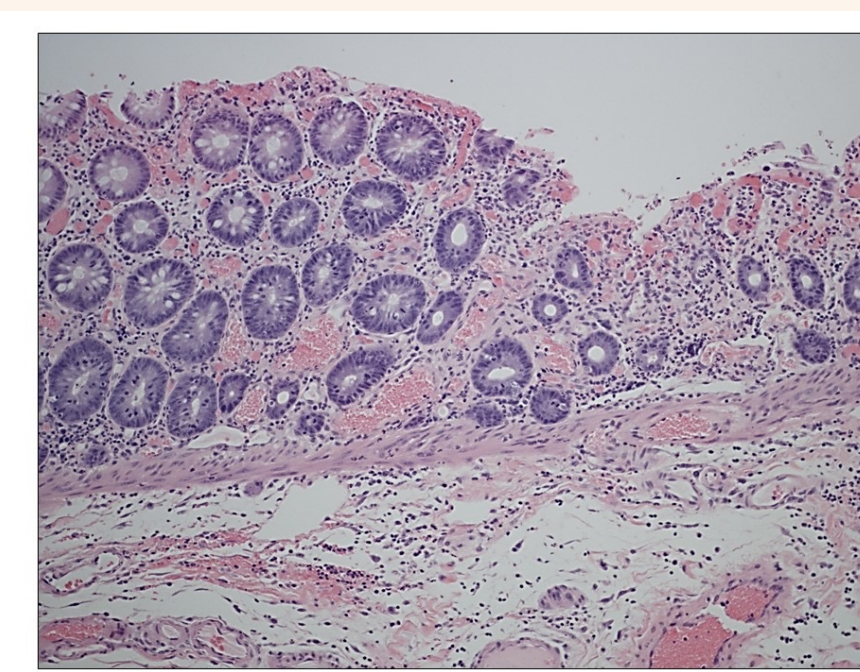
## IMAGES



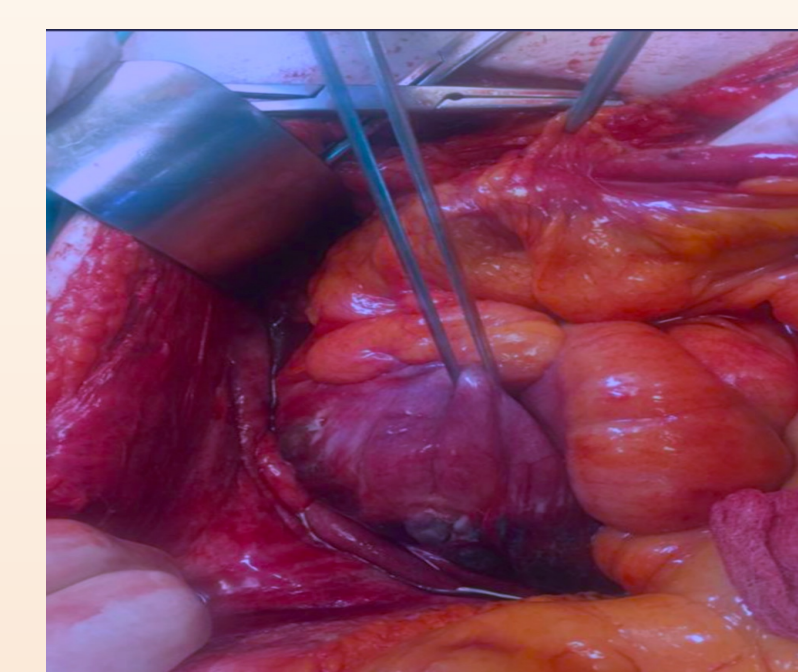
Chest X-ray of our patient showing vascular congestion and bilateral pulmonary infiltrates consistent with COVID-19 infection.



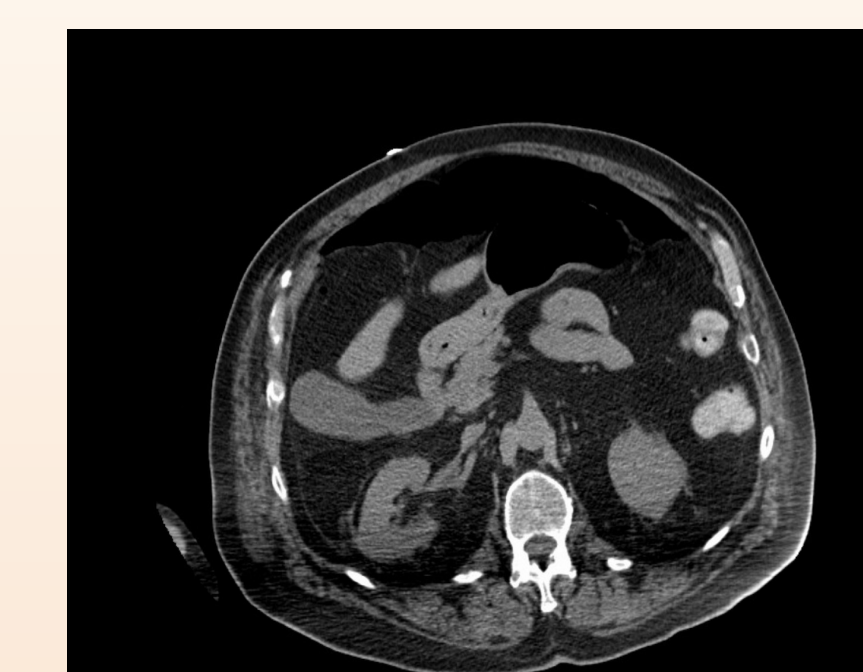Perforation site showing marked surface injury on hematoxylin & eosin (H&E) stain at 40 times magnification.



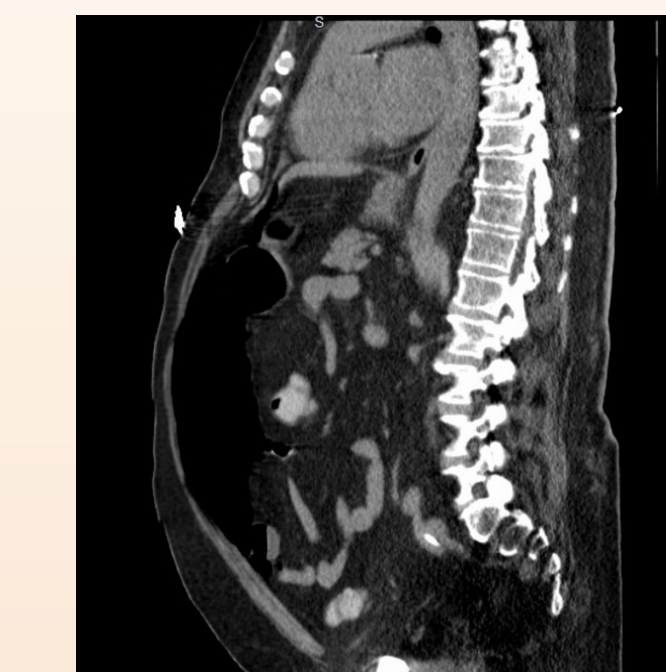Perforation site on hematoxylin & eosin (H&E) stain at 200x showing marked surface injury, mucin loss in atrophic crypts, hyalinization of lamina propria, residue glands more closely spaced, vascular congestion and acute inflammation.



Perforation site during exploratory laparotomy: Post-debridement and wash after removal of surrounding necrotic tissue and collections.



CT chest of our patient (axial view) showing intraperitoneal free air in the anterior abdominal wall.



CT chest of our patient (sagittal view) showing extensive intraperitoneal free air in the anterior abdominal wall present non-dependently.

## RESULTS

- ACE2 protein, a cell receptor for SARS-CoV-2, has been found in glandular cells of gastrointestinal epithelia. Direct viral infection, small vessel thrombosis, or nonocclusive mesenteric ischemia are some possible explanations for the spectrum of bowel findings.
- SARS-CoV-2 can have direct inflammatory effect on vascular endothelium too. Use of steroids, tocilizumab and systemic coagulopathy seen in severe COVID-19 infection also contributes to these manifestations.
- In our patient, an acute over-distension of colon, without mechanical distal obstruction, in the setting of COVID-19 infection & tocilizumab led to cecal perforation.

## SUMMARY / CONCLUSION

- GI perforation is a rare but dangerous complication of COVID-19. Treatment with interleukin-6 inhibitors or steroids is often associated in most cases. As we are gaining more knowledge about clinical spectrum of this novel disease, we are learning more about its possible rare expression, associations, and complications.
- Our case underlines the need to be vigilant for severe GI symptoms in setting of COVID-19 infection to enrich our understanding of this pandemic and as a result improve patients' outcome.