

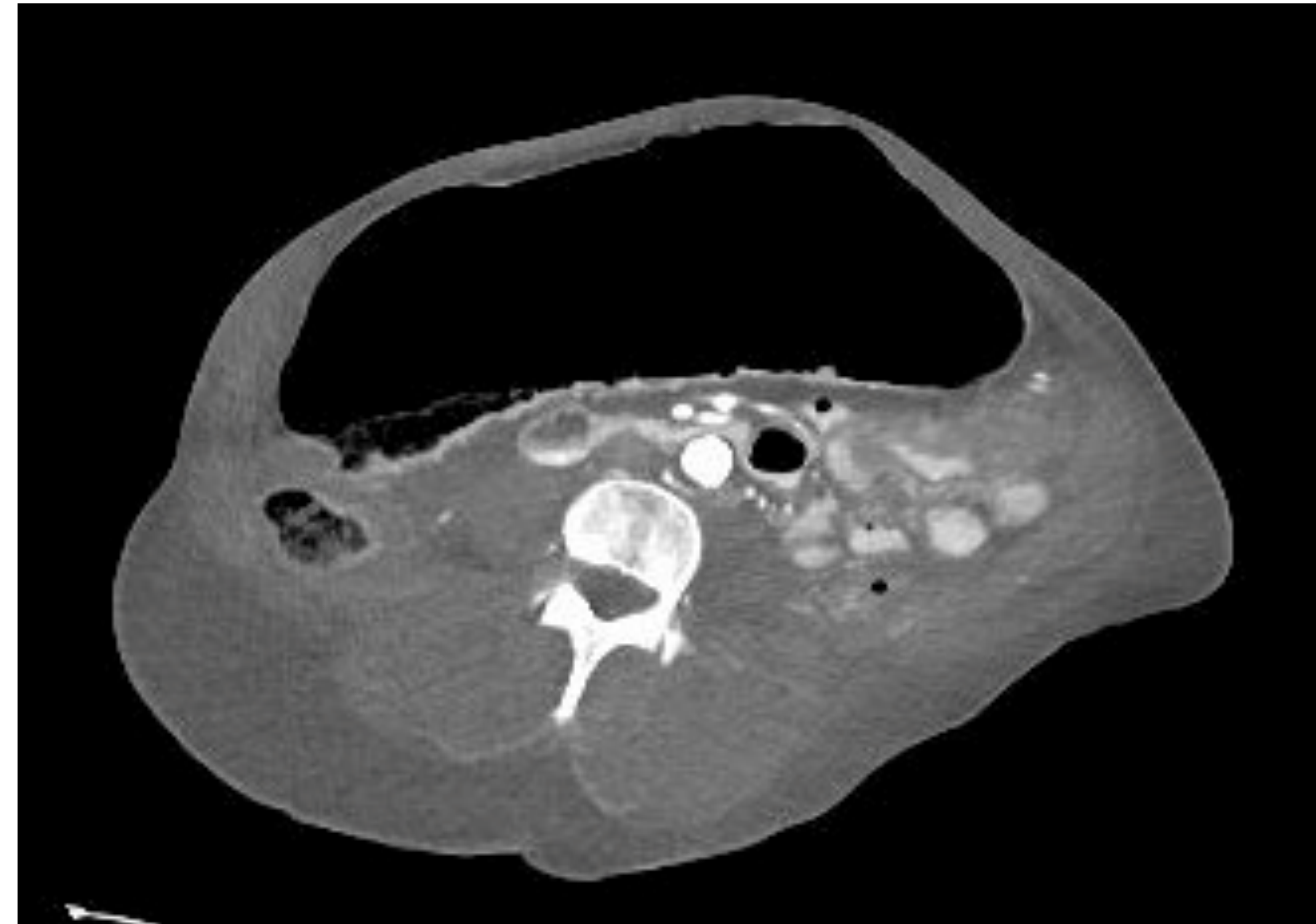
## Introduction

- Colonic pseudo-obstruction is a rare complication of AL Amyloidosis that is described as a diffuse colonic dilation without underlying mechanical cause.
- In AL Amyloidosis, extracellular protein deposits disrupt tissue structure and function.
- Manifestations of colonic involvement of AL Amyloidosis include chronic diarrhea, weight loss, abdominal pain, and pseudo-obstruction.
- Here we present a patient with worsening abdominal pain and distention, found to have colonic pseudo-obstruction likely from AL Amyloidosis. Her symptoms improved with colonic decompression and with the utility of prokinetic agents.

## Case Presentation

- A 79-year-old female presented with 3 days of progressively worsening abdominal pain and distention, with associated constipation.
- Her past medical history was significant for anemia, AL-Amyloidosis diagnosed 4 months prior to arrival, and PEG placement 3 weeks prior to arrival due to worsening dysphagia secondary to macroglossia.
- Vital signs were normal. She did not appear in acute distress and was hemodynamically stable.
- Pertinent examination findings included abdominal distention, decreased bowel sounds, and diffuse abdominal tenderness.

## Images



**Figure 1:** CT Abdomen Pelvis revealed marked dilation of the transverse colon.

## Case Presentation (Cont.)

- Pertinent labs included WBC 5.6 k/uL, albumin 2.1 g/dL, AST 39 U/L, ALT 43 U/L, ALP 196 U/L, and total bilirubin 0.3 mg/dL.
- Clostridium difficile, giardia lamblia, salmonella, and stool occult blood were negative.
- CT abdomen and pelvis revealed gaseous distention of the transverse colon and diffuse colonic wall thickening, as displayed in figure 1.
- Colonoscopy revealed diffuse dilation of the transverse colon, with components of inflammation including friability and loss of vascularity.
- Decompression was successfully performed through colonoscopy. The patient tolerated the procedure well and had marked improvement of abdominal distention and pain. Her percutaneous tube feeds were reinitiated and tolerated well.

## Discussion

- Colonic pseudo-obstruction is a rare complication of AL Amyloidosis that is caused by deposits of protein in extracellular tissue.
- AL Amyloidosis is a multisystem disease that rarely presents with colonic manifestations.
- However, colonic manifestations may be the sole presentation of AL Amyloidosis.
- Colonic pseudo-obstruction remains a clinical challenge and can lead to bacterial overgrowth and malnutrition.
- Here we demonstrate successful air decompression of a colonic pseudo-obstruction due to AL Amyloidosis. We hope to increase awareness of AL Amyloidosis as an etiology colonic pseudo-obstruction.