

Introduction

- Third space endoscopy, or submucosal endoscopy, is a non-invasive procedure used to access deeper layers of the gastrointestinal tract by creating a submucosal tunnel.
- Examples include peroral endoscopic myotomy (POEM), submucosal tunneling endoscopic resection (STER), peroral endoscopic tunneling (POET), peroral endoscopic tunneling for restoration of the esophagus (POETRE), peroral pyloromyotomy (POP), and submucosal tunneling endoscopic septum division (STESD).
- POEM was introduced in the last decade to treat primary achalasia and has since been developed into different techniques including gastric POEM (G- POEM), Zenker’s POEM (Z-POEM), and non-Zenker’s diverticulum POEM (D-POEM).
- Most procedure videos are edited making it difficult to learn the entire procedure. The aim of this poster is to show entire procedures with unedited POEM videos.

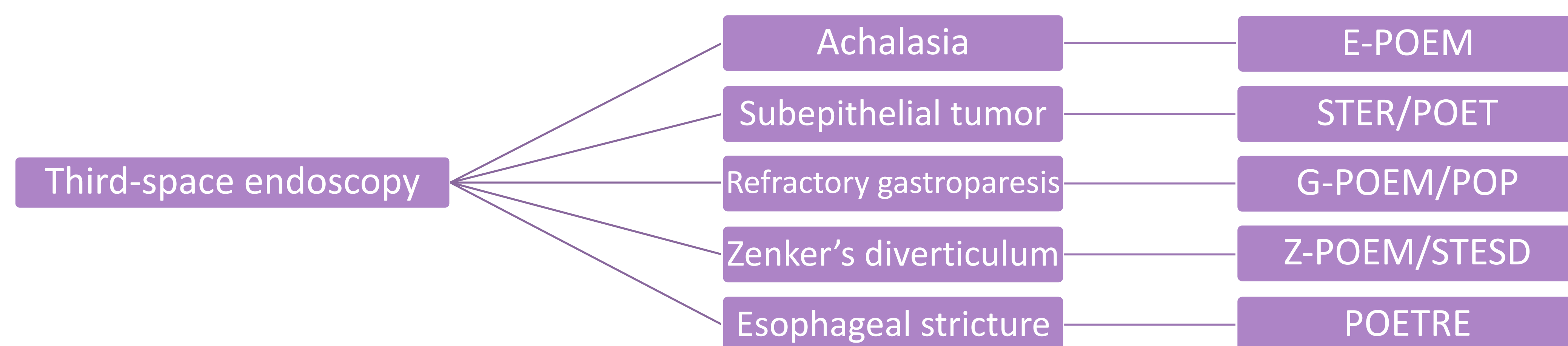


Figure 1. Third-space endoscopic procedures and their indication.

Case Description and Methods

	Case 1	Case 2	Case 3	Case 4
Age & Gender	36-year-old female	40-year-old female	70-year-old male	75-year-old male
Procedure	E-POEM	G-POEM	Z-POEM	D-POEM
Indication	Multiple year history of dysphagia	5-year history of diabetic gastroparesis with daily nausea and vomiting; refractory to medical management	Multiple year history of dysphagia, regurgitation, and weight loss	Multiple year history of dysphagia and occasional vomiting
Endoscopic Findings	Type 11 achalasia on esophageal manometry	None	5 cm Zenker’s diverticulum	5-6 cm diverticulum in distal esophagus
Procedure Time	9 minutes	8 minutes	10 minutes	10 minutes
Complications	None	None	None	None
Outcomes	Patient reported reduction of symptoms. Eckardt score decreased from 7 to 2.	Patient reported a reduction of symptoms. Gastroparesis cardinal symptoms index decreased from 3.5 to 1.5.	Patient reported reduction of symptoms and improvement in food tolerance 1 month after the procedure.	Patient reported improvement of symptoms.


Table 1. Case Description

Discussion

- POEM is done by the following steps:
 - Submucosal bleb raising
 - Mucosal incision
 - Tunnelling in the submucosa
 - Myotomy with hybrid knife
 - Closure of the mucosal incision with endo clips
- Potential complications of POEM include bleeding, mucosal perforation, gastro-esophageal reflux, pneumoperitoneum, pneumomediastinum, pneumothorax, etc.
- The procedure time in published literature is usually about 1 hour. The key and potentially most time-consuming step is to create a submucosal tunnel. Our experience is to create a submucosal space large enough for the head of the scope. In experienced hands, 10 minutes for POEM is possible.

Conclusions

- POEMs can provide symptomatic relief in patients with achalasia, in patients with Zenker’s and Non-Zenker’s diverticulum and in patients with different etiologies of gastroparesis.
- Additional endoscopic training is required to carry out third space endoscopic procedures.
- Further research is necessary to validate the long-term outcomes of these procedures.



Please scan this QR code to access our unedited POEM videos.

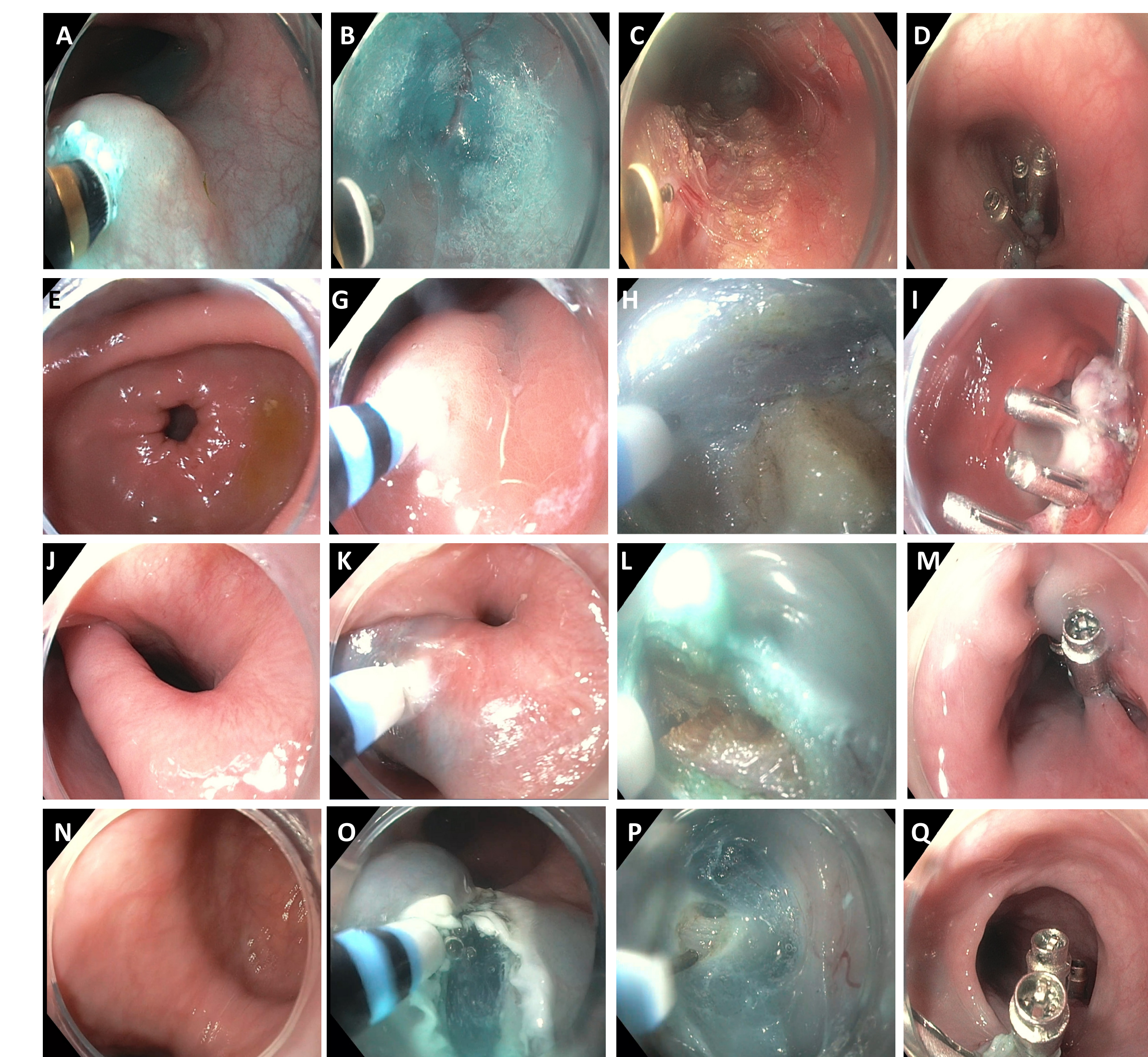

Figure 2. Endoscopic pictures. (A-D): E-POEM; (E-H): G-POEM; (J-L): Z-POEM; (M-P): D-POEM

References

1. Gonzalez JM, Benezech A, Barthelet M. Complications of submucosal endoscopy. *Best Pract Res Clin Gastroenterol.* 2016;30(5):783-791. doi:10.1016/j.bpg.2016.10.015
2. Nabi Z, Nageshwar Reddy D, Ramchandani M. Recent Advances in Third-Space Endoscopy. *Gastroenterol Hepatol (N Y).* 2018;14(4):224-232.

Contact

Grace Ann McCurdy, BS, MS
LSU Health Shreveport
gam002@lsuhs.edu
Phone: 318-344-5170