

Anti-Inflammatory Activity of Lefamulin in a Mouse Model of Influenza Virus H1N1 Infection

W. W. Wicha¹, S. Kimber², C. Cumper², H.S. Lam², L. S. Ballesteros², C. Kirkham², C. Richards², Jared L. Crandon³, S. P. Gelone³, S. Paukner¹

¹Nabriva Therapeutics GmbH, Vienna, Austria, ²Charles River Discovery - Portishead (United Kingdom), ³Nabriva Therapeutics US, Inc., Fort Washington, PA, USA

ABSTRACT

Background: Lefamulin (LEF) is a pleuromutilin antibiotic approved by the United States (US) FDA for the treatment of community-acquired bacterial pneumonia in adults. In addition to the potent antibacterial activity, LEF has demonstrated anti-inflammatory activity in an LPS induced lung neutrophilia model in mice. We investigated the anti-inflammatory activity of lefamulin in the H1N1 influenza mouse model in comparison to oseltamivir (OTV) and azithromycin (AZM).

Methods: Infection was performed in BALB/c mice by intranasal challenge with ~70 PFU influenza virus H1N1 A/PR/8/1934 (Day 0). Treatment with drugs at clinically relevant doses started on Day -1 (LEF 70 mg/kg/day and 110/140 mg/kg/day, subcutaneous (SC), AZM 30 mg/kg/day, intraperitoneal (IP) and OTV 20 mg/kg/day per-oral (PO)) to Day 6. On Days 3 and 6, bronchioalveolar lavage fluid (BALF) was collected to measure infiltrating lung leukocytes and cytokines. Lung immunopathology following infection was evaluated on Day 6 by gross pathology at termination together with hematoxylin and eosin histopathology.

Results: In untreated vehicle control animals, the influenza infection progressed as expected with bodyweight loss, increased cell infiltration into the lung and increased levels of TNF- α , IL-6 at day 3 and 6. Treatment with LEF significantly decreased the total immune cell infiltration into the lung by day 6 at both doses tested (Figure 1A). Cytokine levels in the BALF were significantly reduced on day 3 when the viral load peaked. Furthermore, LEF showed positive effects on lung gross pathology and survival. OTV and LEF, at both doses, appeared efficacious in the suppression of the development of influenza induced bronchi-interstitial pneumonia, whereas azithromycin didn't show reduced pathology (Figure 1B).

Conclusions: LEF showed anti-inflammatory treatment following acute influenza virus infection. Following influenza infection LEF was able to significantly reduce lung immunopathology and improve clinical outcome in mice. Results from this experiment were consistent with that observed in the LPS induced lung neutrophilia mouse model. Further studies are warranted to evaluate the immunomodulatory potential of LEF.

INTRODUCTION

- 'Cytokine storm' defines a combination of cytokines and cellular components that result in an excessive and aberrant inflammatory response that damages host tissues and that, in the alveolar lung environment, may result in acute lung injury (ALI).
- ALI is characterized by an acute mononuclear/neutrophilic inflammatory response followed by a chronic fibroproliferative phase marked by progressive collagen deposition in the lung. ALI, and its more severe form acute respiratory distress syndrome (ARDS) may be direct consequences of both, bacterial pneumonia or pneumonia caused by viruses including e.g. influenza virus¹ or SARS-CoV-2. As a consequence, the inhibition of excessive cytokine production has been recognized as a therapeutic target.
- The influenza virus H1N1 infection model in mice is an established model for the evaluation of anti-inflammatory/immune-modulatory activity of therapeutics, that may or may not display antiviral activity.²
- This study evaluated the anti-inflammatory/immune-modulatory activity of LEF, an antibacterial agent approved for the treatment of community-acquired bacterial pneumonia.

METHODS

Adult female BALB/c mice (n=15 per group) were challenged with influenza virus H1N1 A/PR/8/1934 by intranasal (IN) administration of 35 μ L at ~100 TCID₅₀ units (70 PFU) on Day 0. Treatment with drugs started on Day -1 (pre-treatment) and continued to Day 6 (dosing regimens see Table 1). BALF was collected on Days 3 and 6 for analysis of infiltrating lung leukocytes (viable CD45+ cells) by flow cytometry (BD LSR-Fortessa-X20), cytokines (Bio-Plex 200, BioRad) and virus titres. At Day 6 lung tissue was assessed for gross pathology and viral titre, and a small lobe was preserved in fixative for histopathology.

Group	Dose and Regimen	Treatment Days
Naïve (uninfected)	N/A	
Vehicle control (WFI ^a)	BID N/A sc	Days -1 to 6
Lefamulin (Regimen 1)	BID 35 mg/kg SC	Days -1 to 6
Lefamulin (Regimen 2)	TID 35 mg/kg SC BID 70 mg/kg SC	Days -1 to 2 Days 3 to 6
Azithromycin	BID 15 mg/kg SC BID 15 mg/kg IP	Days -1 to 0 Days 1 to 6
Oseltamivir	QD 20 mg/kg PO	Days -1 to 6

a, water for injection

RESULTS

- In untreated vehicle control animals, the influenza infection progressed as expected with bodyweight loss, increased cell infiltration into the lung and increased levels of TNF- α , IL-6 at day 3 and 6.
- The antiviral Oseltamivir appeared efficacious in the suppression of the development of influenza induced bronchi-interstitial pneumonia, whereas the immune-modulatory azithromycin didn't show reduced pathology (data not shown in Figure).
- Lefamulin had a positive outcome on lung consolidation and survival across the study.
- Treatment with Lefamulin significantly decreased the total immune cell infiltration in the lung by day 6 at both doses tested, while that of the anti-inflammatory antibiotic Azithromycin and the antiviral Oseltamivir groups was similarly high as the vehicle control (Figure 1A).
- By Day 6, Lefamulin significantly decreased neutrophils, natural killer cell, CD4 and CD8 T-cell infiltration in the lung at both doses tested, while B cells reduction was only significant for LEF regimen 2 (data not shown).

- Lefamulin treatment resulted in a dose-dependent and significant reduction in bronchial degeneration and alveolar inflammation resulting in an overall significant reduction in histopathology score in dosing regimen 2 group (Figure 1B).
- Azithromycin, in contrast, didn't result in significantly different histopathology scores than the vehicle group (Figure 1B).
- Both Lefamulin doses resulted in significant decreases of the pro-inflammatory cytokine IL-6 and TNF- α levels in BALF in comparison to the vehicle control on day 3, when the viral load peaked (Figure 1C-D).
- Overall, Lefamulin, at both doses, but more notably at the higher dose (regimen 2) successfully suppressed the development of broncho-interstitial pneumonia induced by influenza virus A/Puerto Rico/8 (H1N1) challenge.

CONCLUSIONS

- Lefamulin demonstrated anti-inflammatory activity following acute influenza virus H1N1 infection in mice.
- Lefamulin was able to significantly reduce the lung immunopathology and improve the clinical outcome by a significant reduction in bronchial degeneration and alveolar inflammation.
- Results from this study were consistent with that observed in the LPS induced lung neutrophilia mouse model that demonstrated reduced cytokine concentrations in BALF and reduced infiltration of the lung by inflammatory monocytes and neutrophils.³
- Further studies are warranted to evaluate the immunomodulatory potential of Lefamulin and its relevance in the treatment of bacterial and viral pneumonia as well as other diseases of the lower respiratory tract.

REFERENCES

- (1) Short KR et al. (2014) Pathogenesis of influenza-induced acute respiratory distress syndrome. *Lancet Infect Dis* 14:57-69
- (2) Zimmermann P, et al. (2018) The immunomodulatory effects of macrolides - a systematic review of the underlying mechanisms. *Frontiers in Immunol* 9:302
- (3) Hafner M., et al. Anti-inflammatory activity of lefamulin versus azithromycin and dexamethasone in vivo and in vitro in a lipopolysaccharide-induced lung neutrophilia mouse model. *PLoS One*. 2021;16(9), article e0237659

Acknowledgments

This study was supported by Nabriva Therapeutics. Charles River Discovery-Portishead received compensation fees for services related to preparing this poster.

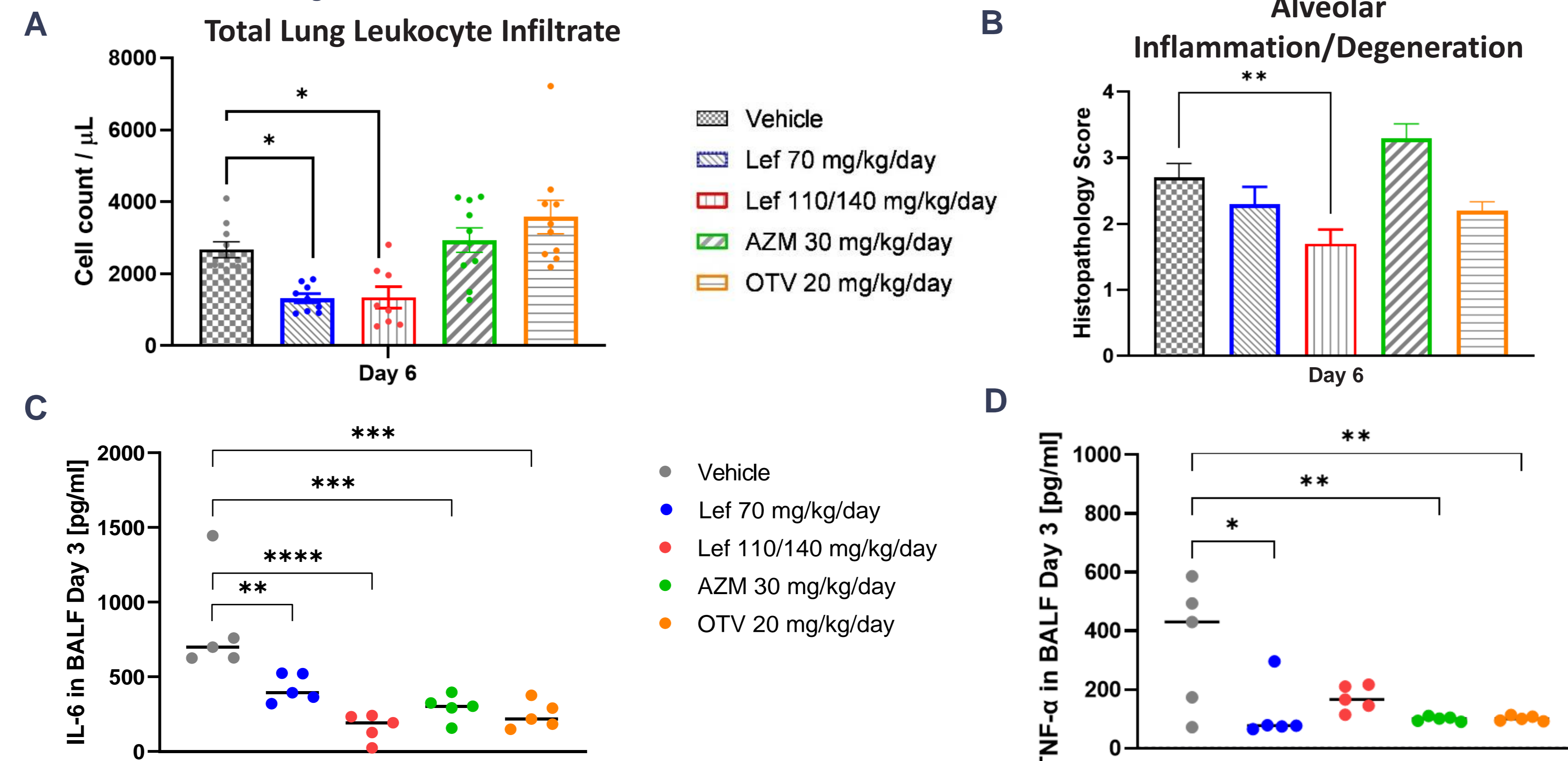
Disclosures

Wicha W., Crandon J., Gelone S. and Paukner S. are employees and stockholders of Nabriva Therapeutics plc.



Scan this QR code with your electronic device to receive a PDF file of the poster or visit www.nabriva.com/news

Figure 1. Total immune cell infiltration (viable CD45+ cells) in BALF (A) and degeneration histopathology score of the lung (B) on Day 6 (bars represent mean \pm SEM, n=10), and cytokine IL-6 (C) and TNF- α (D) concentrations in BALF on Day 3 (n=5) following intranasal influenza virus H1N1 challenge.



Statistical significance between the control and treatment groups were determined using One-way ANOVA with Dunnett's post-hoc test. * - p < 0.05, ** - p < 0.005, *** - p < 0.0005, **** - p < 0.0001.